6 Diagnosing Injuries of the Skull Base

→ Flowchart Injuries of the Skull Base, Chapter 3, p. 17.

→ Treatment of Injuries of the Skull Base, Chapter 17, p. 140.

Surgical Anatomy

The bony architecture of the skull base can be divided into three depressions: the anterior, middle, and posterior cranial fossae.

The interior surface of the cranial base is comprised of the following (Fig. 6.**1**):

- ethmoid bone;
- frontal bone;
- sphenoid bone;
- temporal bone;
- occipital bone.

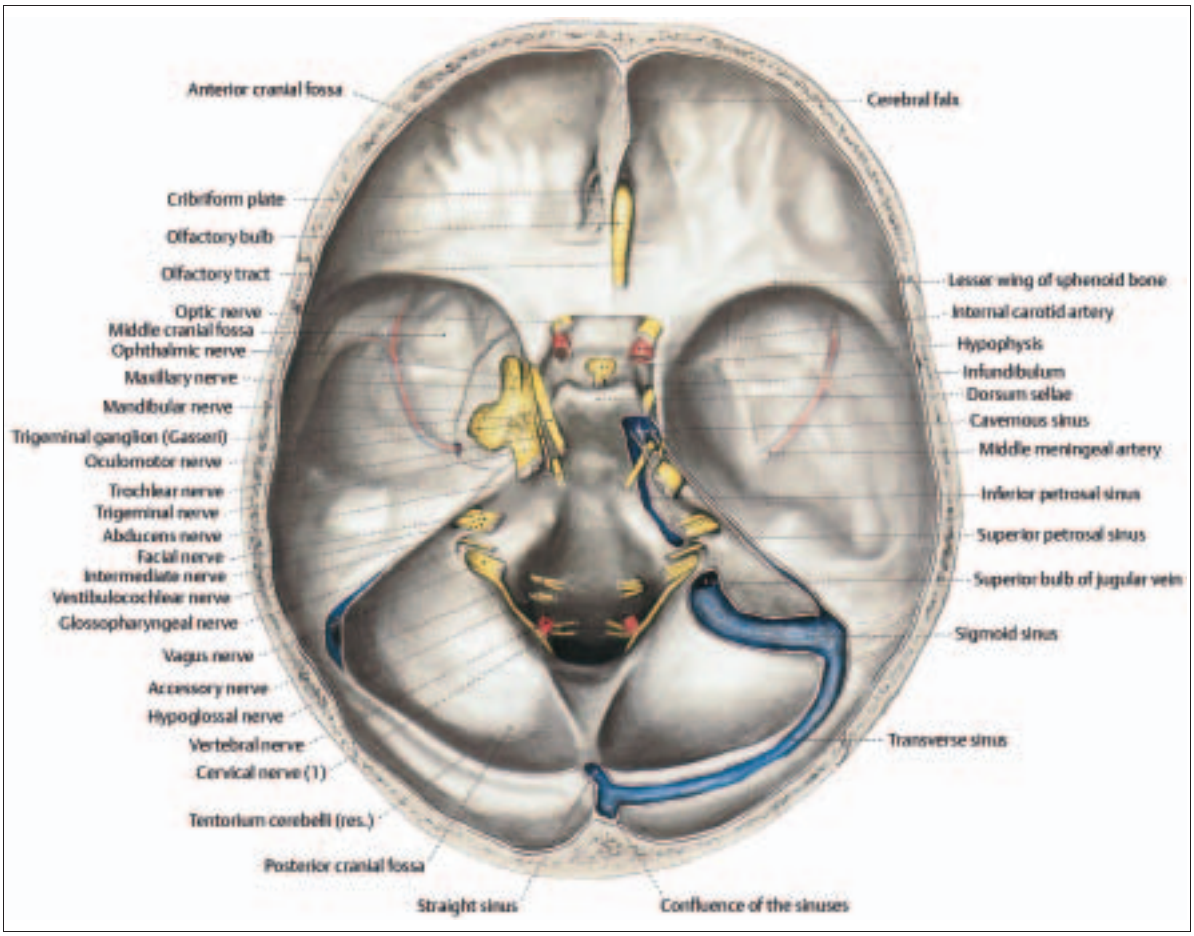

Fig. 6.**1** Overview of the anatomic structures of the skull base (from Tillmann 1997).

Ernst/Herzog/Seidl, Head and Neck Trauma (ISBN 3131400013, 9783131400017),
© 2006 Georg Thieme Verlag KG

Anterior Cranial Fossa

The anterior cranial fossa is made up of two bones: the ethmoid bone and the frontal bone. These form the floor, sides, and anterior wall of the cranial base. The boundary to the middle cranial fossa is formed by the lesser wings of the sphenoid bone. The anterior skull base provides the roof for the pair of orbital cavities and the upper portion of the nasal cavity.

At the center of the anterior cranial fossa is the cribriform plate, part of the ethmoid bone. Traversing the cribriform plate through openings in the plate are the fine olfactory nerves, which are covered by a dural sheath and enclosed in the subarachnoid space. There can be considerable differences in height between the ethmoid bone and the cribriform plate. In the center of the cribriform plate is a sagittally positioned bony process, the crista galli, which is sometimes pneumatized. The cerebral falx, which divides the two halves of the brain, is firmly anchored to the crista galli.

Middle Cranial Fossa

The middle cranial fossa is divided by the pituitary fossa (sella turcica), which contains the pituitary gland at its center. On the posterior side of the pituitary fossa, the clivus slopes down toward the posterior cranial fossa. The pituitary fossa is formed by the sphenoid body with the lesser and greater wings of sphenoid bone:

- The greater wings of the sphenoid bone (ala major) are two bony plates that descend from either side of the pituitary fossa to create part of the floor of the middle cranial fossa.
- The lesser wings of the sphenoid bone (ala minor) travel horizontally toward the lateral cranial fossa.

Between the lesser and greater wings of the sphenoid bone is a gap, the superior orbital fissure, containing the trochlear nerve, abducens nerve, oculomotor nerve, ophthalmic nerve, and superior orbital vein.

The middle cranial fossa is also partially formed by the temporal bone, which is made up of petrous (pyramid), squamous, and tympanic portions. The roof of the tympanic cavity (tegmen tympani) and antrum (tegmen antri) thus forms part of the floor of the middle cranial fossa.

The optic canal, containing the optic nerve and ophthalmic artery, is located in the middle cranial fossa. Lateral to the apex of the petrous pyramid is the trigeminal ganglion of the trigeminal nerve. The trigeminal ganglion emerges as the mandibular nerve from the foramen ovale and as the maxillary nerve from the foramen rotundum. The foramen spinosum transmits the middle meningeal arteries. The foramen lacerum, transmitting the greater superficial petrosal nerve, is located in front of the carotid canal in which the carotid artery lies.

After entering the cranial cavity, the internal carotid artery travels in the carotid canal lateral to the cavernous sinus for a short distance.

Posterior Cranial Fossa

The posterior cranial fossa is separated from the middle cranial fossa by the edge of the petrous pyramid. At the center of the pyramid is the opening to the internal acoustic meatus, which transmits the vestibulocochlear nerve, facial nerve, and labyrinthine vessels.

Directly adjacent to the pyramid is the sigmoid sinus, which flows into the jugular bulb and exits the cranial fossa together with the glossopharyngeal nerve, vagus nerve, and accessory nerve—via the jugular foramen. The foramen magnum is the largest opening in the posterior cranial fossa, allowing entrance of the medulla oblongata and vertebral artery into the cranial cavity.

Enclosing the brain is the dura mater, which is made up of an inner and outer layer. The outer layer forms the periosteal covering of the cranial bone. This internal periosteum is firmly attached near the crista galli. At the posterior wall of the frontal sinuses, the periosteum gradually separates from the bone.

Pathomechanism and Classification

Injuries of the skull base can be divided into bursting fractures and bending fractures.

Pathomechanism

Bending fractures are caused by direct, focused trauma to the skull. Depression of the bone at the site of impact results, which typically produces comminuted or perforated fractures (Fig. 6.**2a**).

Bursting fractures are caused by objects with a wide surface area and indirect trauma to the cranial bones. The resulting force is transmitted and, in areas where the bone is thin, minimal elasticity results in breakage, i. e., bursting fractures (Fig. 6.**2b**).

Ernst/Herzog/Seidl, Head and Neck Trauma (ISBN 3131400013, 9783131400017),
© 2006 Georg Thieme Verlag KG

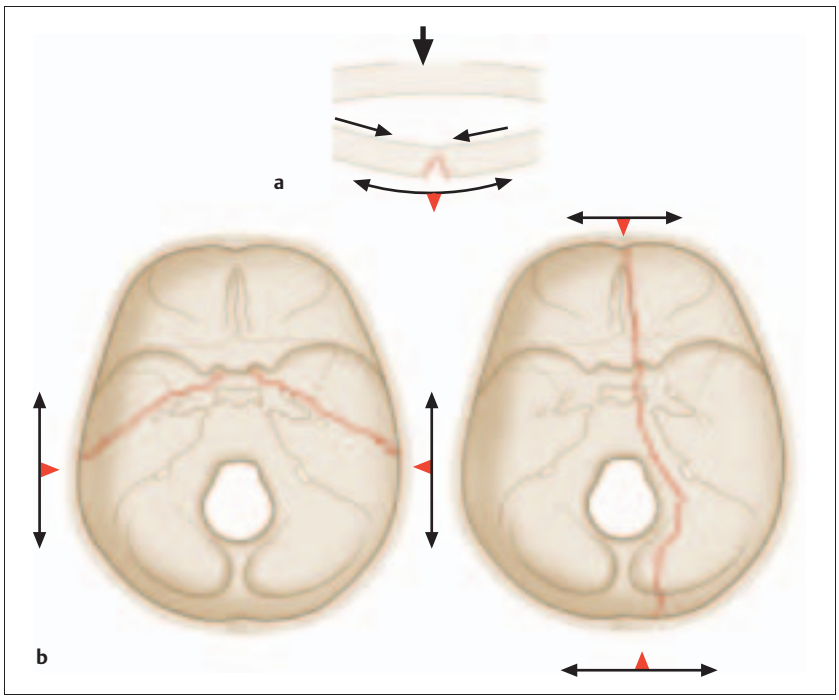

Fig. 6.**2** Etiology of bending (**a**) and bursting fractures (**b**).
a Focused trauma leads to primary fissure formation on the opposite surface of the bone, or to complete fracture, given sufficient force.
b Impact over a broad area of bone leads to compression, and ultimately a bursting fracture of the skull base.

Dural Injury

Osseous injury of the skull base can cause a tear in the dura mater, attached to the bone.

The firm attachment in the nasal fossa region of the dura mater makes this a site at high risk of injury.

The dura mater is a bradytrophic tissue; healing is slow and occurs with connective tissue scar formation. In injuries involving the skull base, resulting swelling of the brain can cause a defect in the cranial base without primary cerebrospinal fluid leak.

The arachnoid membrane closes much more quickly than the dura mater, so that cerebrospinal fluid leakage can no longer be detected. Wound closure with arachnoid tissue, however, *does not* offer sufficient protection against infection arising from the paranasal sinuses.

Classification of Fractures

Injuries of the anterior skull base are classified in various ways. Classification by the anatomic region involved (Fig. 6.**3**) can be made as shown in Table 6.**1**.

Table 6.**1** Classification of anterior skull base fractures

Region I	Posterior wall of frontal sinuses
Region II	Anterior cribriform plate of the ethmoid bone
Region III	Posterior ethmoid
Region IV	Sphenoid sinus
Region V	Orbital roof

Ernst/Herzog/Seidl, Head and Neck Trauma (ISBN 3131400013, 9783131400017),
© 2006 Georg Thieme Verlag KG

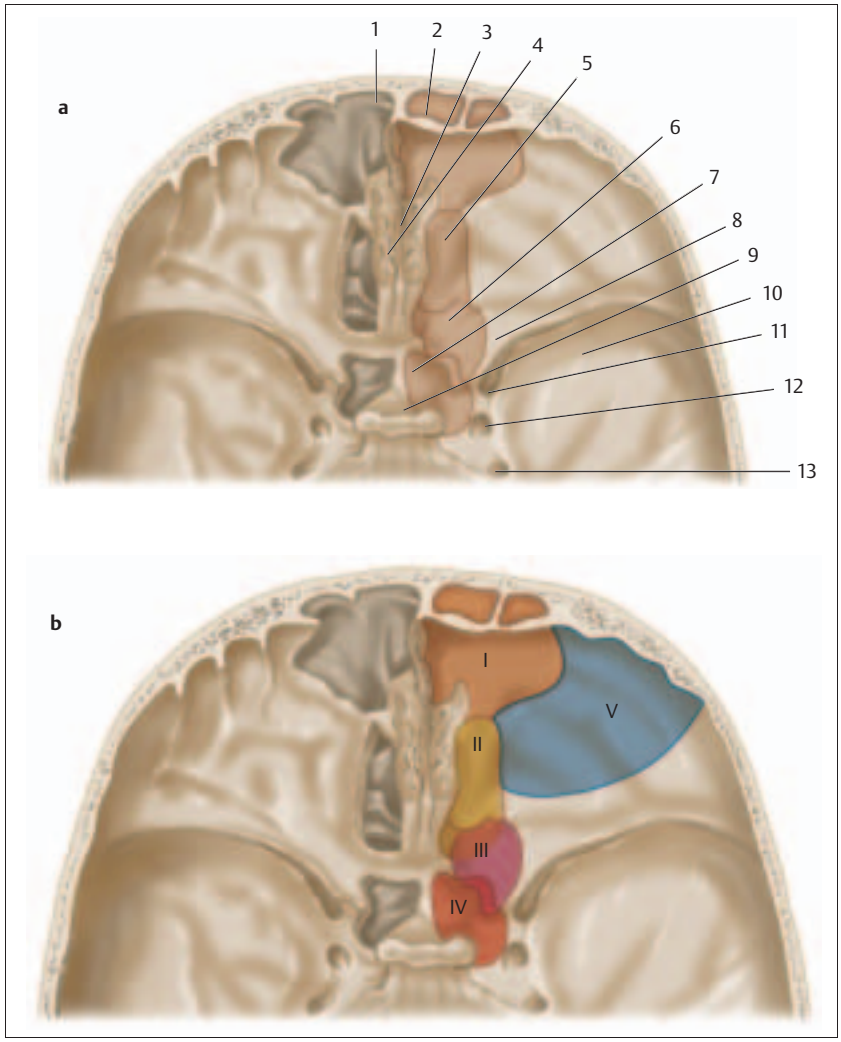

Fig. 6.**3** Anterior skull base.
a Anatomy on a view of the paranasal sinuses. 1 Frontal sinus. 2 Posterior wall of the frontal sinus. 3 Crista galli. 4 Cribriform plate. 5 Anterior/middle ethmoid bone. 6 Posterior ethmoid bone. 7 Sphenoid sinus. 8 Lesser wing. 9 Pituitary fossa. 10 Middle cranial fossa (greater wing of sphenoid). 11 Superior orbital fissure. 12 Foramen rotundum. 13 Foramen ovale.
b Classification of anterior skull base fractures based on anatomic region (for regions I–V see Table 6.**1**, p. 47).

Clinical Signs and Symptoms

Symptoms of injury to the cranial base can be divided into clinically certain and uncertain signs (Table 6.**2**).

Table 6.**2** Clinical signs of an anterior skull base injury

Uncertain signs	Certain signs
Eyelid hematoma, eyelid emphysema	Cerebrospinal rhinorrhea
Epistaxis	Pneumocephalus
Seiferth sign	Early meningitis
Olfactory disturbance	Extruding brain matter

Uncertain Signs of Fracture of the Anterior Skull Base

Eyelid Hematoma, Eyelid Emphysema

Eyelid hematomas can arise from craniofacial injury or from injury of the orbital roof. There is unilateral or bilateral swelling of the upper lids and also blue discoloration in early stages. Swelling can obstruct or impair opening of the eyelid.

! Vision must be tested for any injury involving the region around the eye and eyelid. Instruments (eyelid hooks, etc.) should be used if necessary for opening the lids.

Ernst/Herzog/Seidl, Head and Neck Trauma (ISBN 3131400013, 9783131400017),
© 2006 Georg Thieme Verlag KG

The eyelids are separated by a partition, the orbital septum, allowing localization of injuries in the orbital region. Evaluation is made with eversion of the upper lid (see Fig. 6.**4a**).

- Craniofacial injuries result in visible hematomas ventral to the orbital septum only, which can be seen within a short time following trauma (Fig. 6.**4b**).
- Injuries of the skull base exhibit lid hematomas dorsal and ventral to the orbital septum. Because of the longer distance to the lid, these hematomas may be observed some time after injury occurred (Fig. 6.**4c**).

If air enters the lid apparatus from the nose and paranasal sinuses (e. g., in injuries of the roof of the ethmoid sinus, which radiate into the orbital roof), *orbital (lid) emphysema* results. This can be identified by so-called *air crepitus*.

Epistaxis

Injuries of the mucosa in the cranial base region can result in brief loss of blood from the nose.

Seiferth Sign

The Seiferth sign is a submucosal hematoma visible on the roof of the pharynx that can occur with fractures involving the sphenoid sinus or posterior ethmoid. Flexible endoscopy is used for evaluation.

Olfactory Disturbances

Olfactory disturbances may be caused by direct injury (avulsion of olfactory nerve fibers from the cribriform plate) or indirect injury (hyperextension of the olfactory nerve fibers in shearing movements of the brain) of the olfactory nerve fibers. Various methods can be used to test olfactory ability.

Odorants have a detection threshold and a recognition threshold. Testing substances can be divided into:

- pure odorants that only stimulate the olfactory nerve (coffee, vanilla, cinnamon, gasoline);
- odorants that also stimulate the trigeminal nerve (menthol, formaldehyde, ammonium chloride, vinegar);
- odorants that also stimulate sense of taste (chloroform, pyridine).

In olfactory dysfunction, only stimulants affecting the trigeminal nerve and taste sensation are perceived. Gasoline is an example of a substance suited to performing a simple test of olfactory ability (*subjective olfactory ability test*). A cotton swab dipped in gasoline is held in front of one nostril (with the other nostril closed). If the patient's olfactory sense is intact, he or she will be able to smell the gasoline.

Simulation is tested by placing a pure odorant (e. g., peppermint or cinnamon) on the tongue. If the patient has anosmia, he or she will experience a sweet or cool sensation; if he or she has ageusia, then the sensation will be one of coolness. In the case of simulation, he or she will recognize the olfactant, i. e., the patient retains a sense of smell (*gustatory olfactory test*).

The most common clinical procedure is *semiquantitative analysis of olfactory function*. Solutions with various concentrations of olfactants are used to assess the detection threshold for individual components.

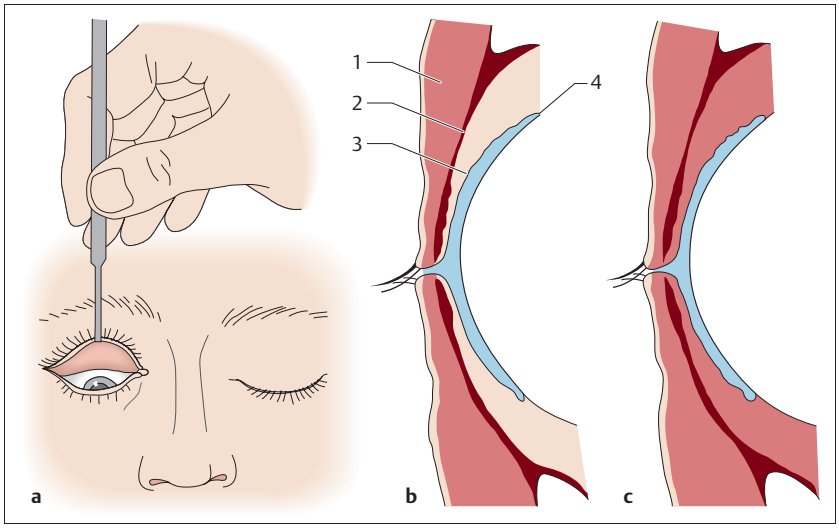

Fig. 6.**4** Eyelid hematomas (Source: Richter 1992).
a Double ectropionized upper lid.
b Lid hematoma ventral to the orbital septum resulting from craniofacial injury or soft tissue damage.
c Lid hematoma arising from the depth of the orbital cone and spreading to the lids. The hematoma is located both ventral and dorsal to the orbital septum.
1 Eyelid skin and orbicularis oculi muscle. 2 Tarsus and orbital septum. 3 Tarsal conjunctiva. 4 Upper fornix.

Ernst/Herzog/Seidl, Head and Neck Trauma (ISBN 3131400013, 9783131400017),
© 2006 Georg Thieme Verlag KG

Objective olfactometry uses selected olfactants in varying concentrations in order to determine stimulated brain activity (gustatory evoked potentials).

Certain Signs of Fracture of the Anterior Skull Base

Cerebrospinal Fluid Rhinorrhea

Leakage of cerebrospinal fluid from a defect can occur:
- as a primary injury following trauma;
- secondarily, i. e., weeks or months after trauma.

Cerebrospinal fluid rhinorrhea can occur only with the presence of a *cerebrospinal fluid fistula*, i. e., communication between intracranial spaces and pneumatized spaces in the facial skeleton.

The most common localization of cerebrospinal fluid fistulae is on the roof of the ethmoid sinus cells. Transmitted forces acting on this region meet with an area of maximum bending; at the same time, the firm attachment of the dura mater to the bone makes it particularly vulnerable to injury.

Cerebrospinal fluid leak can be diagnosed using endoscopy, immunologic methods, contrast radiography, or with dye techniques.

Evaluation of Suspected Cerebrospinal Fluid Rhinorrhea

A suspected cerebrospinal fluid leak always demands further evaluation.

Basic methods for detecting basilar skull injury with CSF leakage are summarized in Table 6.**3**.

Glucose/Protein Analysis

Concentrations of glucose and protein are higher in cerebrospinal fluid than in nasal discharge. One method of detecting cerebrospinal fluid leak is therefore to determine the glucose and protein content of nasal secretions.

A glucose value > 40 mg % and a protein value < 100 mg % (maximum 200 mg %) support a diagnosis of cerebrospinal fluid leak.

The diagnostic value of this test is limited, however, by possible contamination with blood, lacrimal secretion, or saliva. Testing should be done using standard testing strips.

Table 6.**3** Basic clinical tests for detecting cerebral spinal fluid rhinorrhea

Method	Finding
Rhinoscopy	Visible cerebrospinal fluid leakage from the paranasal sinuses
Tissue test	Unlike nasal mucus, CSF does not cause a tissue to stiffen
Filter paper test	Sample of nasal discharge on a filter paper exhibits a light CSF border and a dark central area of blood
Queckenstedt test	Compression of the jugular vein and the resulting intracranial pressure increase leads to increased CSF leakage

Immunologic Diagnosis of CSF Leakage

Detection of beta-2 transferrin is considered part of standard evaluation today when CSF leak is suspected. Testing is essential and must be conducted to exclude injury of the cranial base. If CSF leakage is suspected despite negative results (3 % false negatives), the test can be refined using a dye (fluorescein sodium).

A test sample of discharge is collected in a small vial or on small sponges placed in either nostrils or ears for a period of time. Discharge is then tested for beta-2 transferrin bands using modified gel electrophoresis. The reference range is based on the beta-2 transferrin bands found in the patient's serum.

Diagnostic use of beta trace protein has recently come to the forefront as a further testing method. Specificity is even higher than with beta-2 transferrin.

Dye Methods

Dye methods use intrathecal administration of dye to observe extravasation into the nose and paranasal sinuses as evidence of CSF leakage. Common methods used today include sodium fluorescein dye and CSF scintigraphy, both of which are used especially for detection of occult CSF fluid leaks.

Ernst/Herzog/Seidl, Head and Neck Trauma (ISBN 3131400013, 9783131400017),
© 2006 Georg Thieme Verlag KG

Pneumocephalus

Pneumocephalus is the intracranial presence of air. Increased pressure in the nose and paranasal sinuses causes air to leak through the defect in the bony skull base resulting in epidural, subdural/subarachnoidal, or intracerebral presence of air.

Free air can be detected using diagnostic imaging techniques.

Early Meningitis

Early meningitis refers to onset of meningitis within a matter of a few hours or days following injury. It is caused by infection ascending into cerebrospinal fluid filled spaces. Typical signs of meningitis are drowsiness, neck stiffness, and positive Kernig or Lasègue signs.

Diagnosis is confirmed with a lumbar puncture.

Diagnostic Imaging of Fractures of the Anterior Skull Base

The current standard in diagnosis of suspected fracture of the anterior skull base is computed tomography (CT). Images are taken in the axial (frontal sinus and lateral wall of the sphenoid sinuses) and coronal (cribriform plate and ethmoid roof) planes.

Conventional radiography should be limited to its use as a screening tool for such fractures. For CT imaging and evaluation of anterior skull base fractures caused by osseous displacement, the increment between slices should be at least 2 mm to ensure visualization; for imaging the sphenoid sinuses, increment between slices should be 4 mm (Fig. 6.**5a,b**).

Detection of intracerebral air is a definite sign of fistula (even without osseous displacement). Localization of pneumocephalus can be subdural, subarachnoidal, or epidural.

Another method of localizing cerebrospinal fistulae is the use of intrathecal administration of iotrolan with computed tomography and magnetic resonance imaging evaluation (Fig. 6.**5c**).



Fig. 6.**5** Injuries of the anterior skull base.
a Fracture (*arrow*) in region II of the right side of the skull base.
b Fracture (*arrow*) in region II of the left side of the skull base.
c Visible leakage of iotrolan in the paranasal sinuses during MRI examination as evidence of an anterior skull base fracture (see CT in **b**).

Ernst/Herzog/Seidl, Head and Neck Trauma (ISBN 3131400013, 9783131400017),
© 2006 Georg Thieme Verlag KG

Surgical Indications in Injuries of the Anterior Skull Base

Operative management is indicated for any injury of the cranial base involving osseous displacement >3 mm or with positive detection of cerebrospinal fluid leakage or pneumatocephalus (Table 6.4).

Without surgery, there is a risk of persistent cerebrospinal fluid leakage through the opening, with a threat of ascending infection. Delayed meningitis is a particular concern. Operation scheduling should be based on findings as well as on the patient's overall health.

If there is no primary detection of cerebrospinal fluid leak or pneumocephalus despite apparent osseous displacement, additional immunologic diagnostics and/or cerebrospinal fluid analysis using dye techniques are needed—and are also an essential part of interval treatment.

➔ Treatment of Injuries of the Skull Base, Chapter 17, p. 140.

Absolute surgical indications	Open craniocerebral injury, encephalocele, penetrating injuries
	Intracranial hemorrhage
	Detection of cerebrospinal fluid leak or pneumocephalus
	Orbital complications: compression (hemorrhage); progressive vision impairment; blindness
	Early meningitis
Relative surgical indications	Basilar skull fractures without detection of cerebrospinal fluid leak
	Injuries involving aesthetic disfigurement or functional dysfunction
	Delayed complications such as mucocele and pyocele

Table 6.**4** Overview of surgical indications for fractures of the anterior skull base

Ernst/Herzog/Seidl, Head and Neck Trauma (ISBN 3131400013, 9783131400017),
© 2006 Georg Thieme Verlag KG