Definition

- **Epidemiology**
  Rare complication after kidney transplantation • Occurs in less than 5% of cases • Usually occurs in the first week postoperatively.
- **Etiology, pathophysiology, pathogenesis**
  Hypovolemia • Vein compression due to local fluid accumulation (hematoma, abscess, urinoma, lymphocele) • Stenosis at the anastomosis • Acute rejection.

Imaging Signs

- **Modality of choice**
  Color Doppler ultrasound.
- **Ultrasound findings**
  Enlargement of the transplant kidney with loss of corticomedullary differentiation.
- **Color Doppler ultrasound findings**
  Reduced perfusion of the renal cortex • No flow signal in the renal vein • Retrograde diastolic flow in the intrarenal arteries.
- **MRI**
  MR venography can be used to confirm the diagnosis.

Clinical Aspects

- **Typical presentation**
  Painful swelling of the transplant • Diuresis suddenly ceases • Retention values increase.
- **Therapeutic options**
  Thrombectomy.
- **Course and prognosis**
  Infarction often occurs with loss of the organ.
- **What does the clinician want to know?**
  Reasons for the organ dysfunction.

Differential Diagnosis

Transplant renal artery stenosis	– Direct and indirect signs of stenosis such as flow acceleration, turbulence, pulsus tardus, and pulsus parvus.
Acute tubular necrosis, acute rejection	– Increased resistance index

Tips and Pitfalls

The retrograde diastolic flow in the intrarenal arteries is pathognomonic of complete transplant renal vein thrombosis.

Wolf, Direct Diagnosis in Radiology. Vascular Imaging
(ISBN 9783131451811), © 2009 Georg Thieme Verlag KG

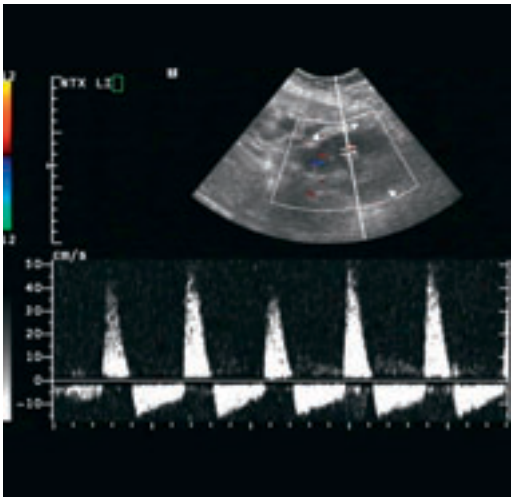

Fig. 6.8 Transplant renal vein thrombosis. Color Doppler ultrasound shows diastolic retrograde flow in a segmental artery, a pathognomonic finding. The margins of the organ are marked by triangles.

Selected References

Akbar SA et al. Complications of renal transplantation. RadioGraphics 2005; 25: 1335–1356

Humar A, Matas AJ. Surgical complications after kidney transplantation. Semin Dial 2005; 18: 505–510

Schenk JP et al. [Radiodiagnosis following kidney transplantation.] Radiologe 1999; 39: 404–414 [In German]