12 Management of Nodal Recurrence

Hisham M. Mehanna, Miroslav Tedla, K. Kian Ang, Christopher M. Nutting

Summary

- Nodal recurrence can be treated successfully in approximately 50% of patients.
- Careful evaluation is necessary to exclude a recurrence at the primary site. PET-CT scanning is the most practical imaging modality for detection of recurrence.
- For the previously untreated neck, treatment of recurrence is by surgery, followed by radiotherapy ± chemotherapy if poor prognostic features are present.
- For previously treated neck, treatment is by surgery + chemotherapy and re-irradiation if possible. Patients should be counseled regarding potential benefits versus late complications.
- Poor prognostic factors include recurrence more than 3 cm in size, recurrence in a previously dissected neck, history of a previous local recurrence before the regional recurrence, extranodal extension, and surgery alone without re-irradiation.

Introduction

Nodal recurrence is the most common type of treatment failure in head and neck cancer.[1] This is often considered to be a very poor prognostic indicator. Many studies report poor outcome of salvage treatments, which are often technically challenging.[2] Furthermore, morbidity from treatment is considerable, posing further dilemmas to patients and clinicians alike. In this chapter, we consider the epidemiology of nodal recurrence in head and neck cancer, current and new investigation modalities, the evidence for the different treatment options available, the outcomes and morbidity associated with these treatments, and special considerations in the management of nodal recurrence.

Incidence and Distribution of Nodal Recurrence

Reported nodal recurrence rates vary according to the site of the primary cancer. Nutting et al. reported a retrospective series of 72 patients presenting with regional recurrence, of whom two-thirds had had previous surgery and all had had previous radiotherapy or chemoradiotherapy. The primary sites were as follows: salivary gland 8%, ear 8%, nasal cavity 1.5%, nasopharynx 4%, oral cavity 24%, oropharynx 22%, larynx 19%, hypopharynx 7%, thyroid 1.5%, occult 6%.[3]

Reported regional recurrence rates vary considerably for the same primary site. This is partly a reflection of the case and stage mix. Ord reported a regional recurrence rate of 8.5% in a retrospective cohort of 349 patients with oral squamous cell carcinoma (SCC) treated surgically by one surgeon.[2] On the other hand, Sun et al. reported a regional recurrence of 19.3% in 233 patients with tongue cancer.[2] Jeong et al. reported an overall regional recurrence of 5.4% in a retrospective study of 436 patients treated for SCC of the larynx;[4] 74% of these recurrences were confined to the neck nodes. Recurrence rates varied by primary site: 4.8% of glottic lesions had a regional recurrence, 6% of supraglottic lesions, and 8.6% of sub/transglottic lesions.[4]

The nodal recurrence rate may also vary according to the type of initial treatment. A systematic review and meta-analysis performed by our group found a nodal recurrence rate of 1.6% in patients who had a neck dissection following complete response to primary radical chemoradiotherapy. In contrast, patients who achieved a complete response but did not have a neck dissection demonstrated 8.2% nodal recurrence rate. The meta-analysis also demonstrated that patients who did not achieve complete response to chemoradiotherapy and therefore had a neck dissection had a nodal recurrence rate of 5.2% following that. These differences were not statistically significant, however (D. Howe, c.c. McConkey, H. Mehanna, unpublished data). The role of PET-CT in the detection of persistent nodal disease after chemoradiotherapy may decrease later recurrence rates due to better detection and earlier management of persistent disease.

Little information is available about the distribution of nodal recurrence. Nutting et al. reported that, in their series of 72 patients, 31% had recurrence in two nodal levels, and 5% in 3 or more levels. Level II was involved in 44 patients, level III in 19 patients, and level IV in 13 patients.[3]

Evaluation of Nodal Recurrence

! Careful assessment of patients who present with nodal recurrence is mandatory, as it is important to answer the following questions as comprehensively as possible, through a combination of investigations, for formulation of a treatment plan:

- What was the previous treatment?
- Is there recurrence at the primary site, too?
- Is there any evidence of distant metastases?
- What is the distribution of the nodal recurrence?
- Is there evidence of nodal extracapsular extension by physical examination and on imaging?
- Is there evidence of involvement and extent of involvement of the carotid arteries, brachial plexus, and prevertebral muscles?
- Can the recurrence be removed surgically with no gross tumor left behind?

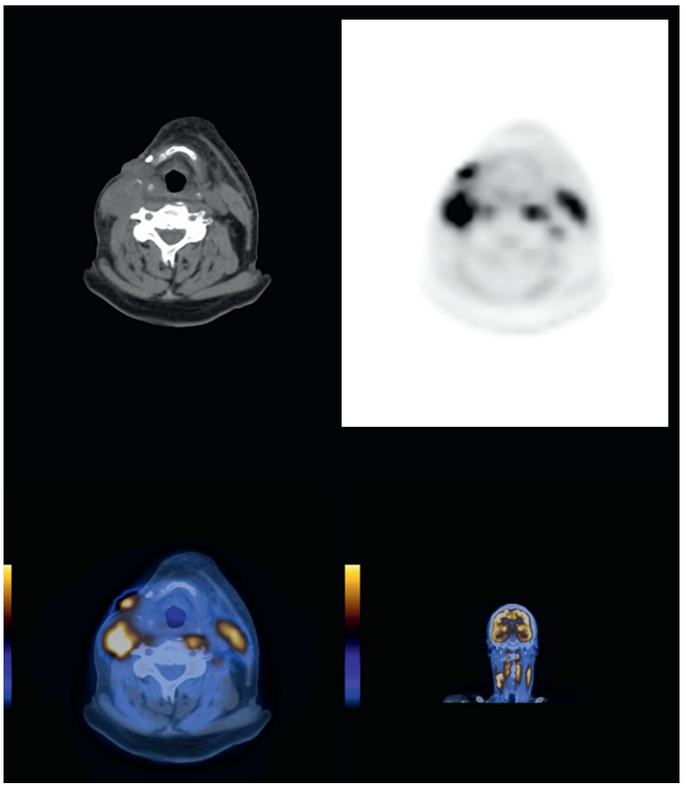

Fig. 12.1 PET-CT scan showing nodal recurrence. (With permission from Dr. Olu Adesanya, consultant radiologist, University Hospital Coventry and Warwickshire, UK.)

History and Examination

The history should elicit the duration of any symptoms suggestive of recurrence. It should also elicit previous treatments in as much detail as possible. The patient's current medical history and performance status should be assessed, as that is often one of the main determinants of eligibility for surgical and nonsurgical treatments. Risk factors such as continuing smoking should also be ascertained.

On examination, fixity of the nodal recurrence should be assessed, as well as the number and distribution of the nodal metastases. A full clinical examination of the primary site and the rest of the upper aerodigestive tract should be undertaken to exclude primary site recurrence and second primaries, respectively.

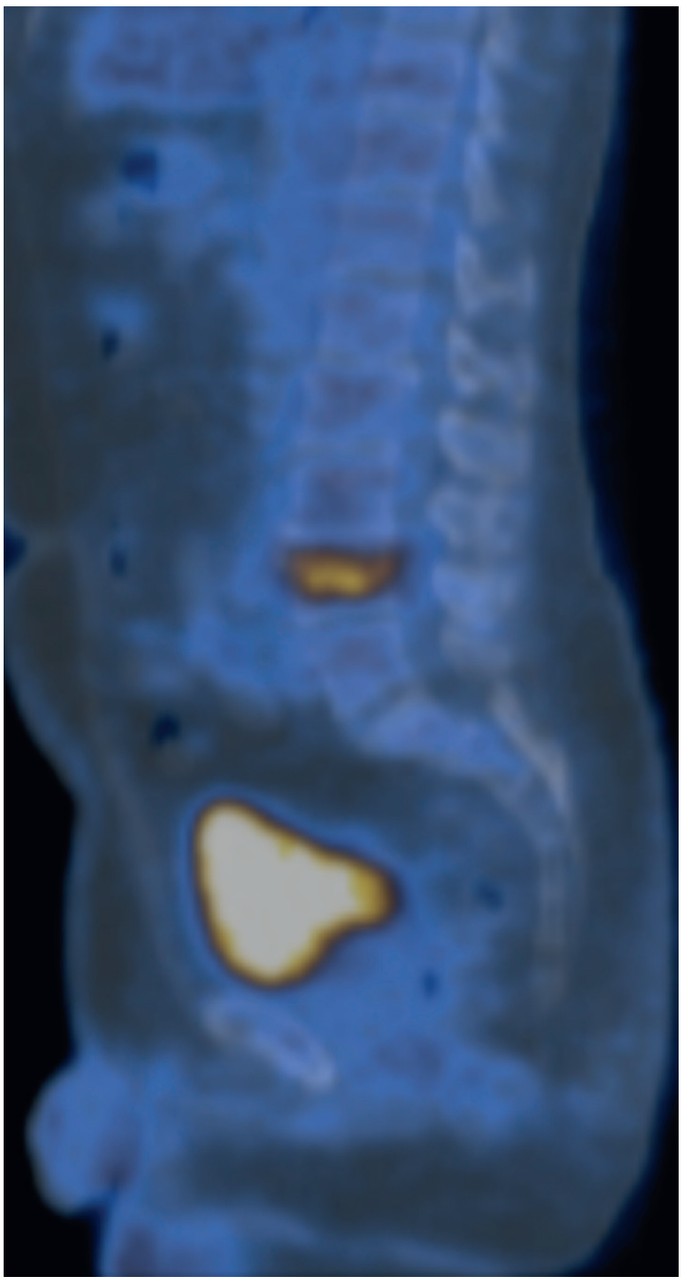

Fig. 12.2 PET-CT showing distant metastasis. (With permission from Dr. Olu Adesanya, consultant radiologist, University Hospital Coventry and Warwickshire, UK.)

Previous Treatment Records

It is important to attempt to obtain the patient's previous treatment records, including details of their operations, radiotherapy plans, all chemotherapy given, any documentation of toxicity, complications and compliance with the treatments. Relapse within high radiation dose regions, for example, indicates that the tumor may be relatively radioresistant, which decreases the expectation for successful outcome with re-irradiation. It is also important to obtain the original diagnostic and resection histopathology specimens, and submit them for review by a pathologist specializing in head and neck cancer to confirm the initial histological diagnosis and identify any poor prognostic factors that the patient may have had that predisposed them to developing recurrence, for example, poor tumor differentiation, vascular and perineural invasion, extranodal extension, and involved resection margins.

Imaging

Computed tomography (CT) or magnetic resonance imaging (MRI) with contrast are appropriate first-line investigations. These allow assessment of the recurrence in the neck, and its relations to the vital structures, especially the carotid artery. It can also allow assessment of the likelihood of extranodal extension. In patients who have had previous surgery, the extent of the previous operations, as well as sacrificed and preserved structures, should be carefully assessed. For example, it should be ascertained whether both internal jugular veins are present and patent.

However, neither of these imaging modalities may be able to accurately assess recurrence at the primary site in some cases. We therefore recommend that additional assessments of the primary site should be undertaken. If available, PET-CT scanning would be the preferred diagnostic modality, as it has been shown to be the

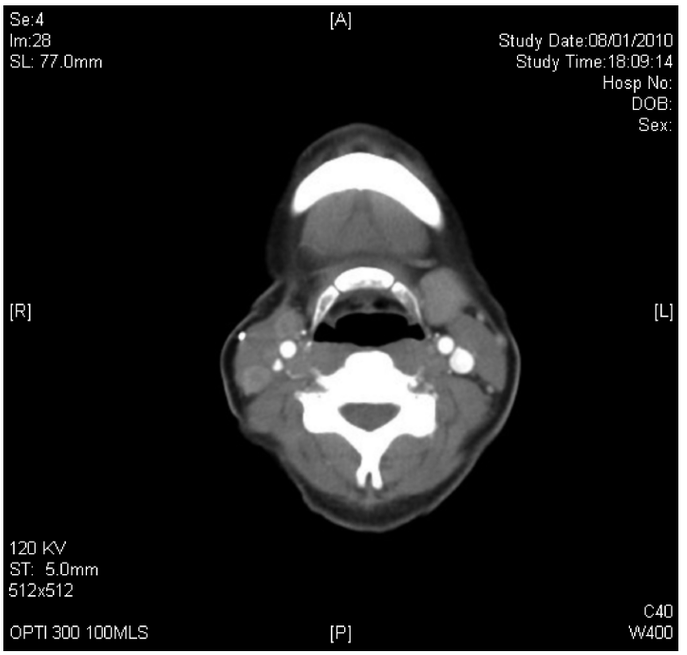

Fig. 12.3 CT of nodal recurrence in the right neck.

most accurate method for assessment of nodal recurrence, exceeding that of CT or MRI. A systematic review and meta-analysis by our group examined 1871 papers and found 27, mainly reporting retrospective cohorts, that were eligible for inclusion.[5] Most studies reported on a combination of patients with persistent nodal disease and patients with recurrent disease. The mean sensitivity of detection of nodal recurrence by PET scanning was 74% (95% CI, 50%–89%), and the mean specificity was 88% (95% CI, 74%–95%). The pooled mean positive and negative predictive values for the detection of recurrent disease in the neck were 49% (95% CI, 29%–70%), and 96% (95% CI, 84%–99%), respectively. Importantly, the sensitivity of the PET-CT scan was significantly higher for scans performed more than 10 weeks after treatment ($P = 0.002$).

A further important advantage of PET-CT is that it may detect distant metastases (**Figs. 12.1 and 12.2**) that are not detected by other modalities, as its sensitivity and specificity for this are very high (92% and 82%, respectively). Importantly, its negative predictive value has been reported to be up to 98% in a follow-up cohort of 80 patients with head and neck cancer.[7] Therefore, if there are no distant metastases on PET-CT scan, then it is extremely likely that there is no current distant metastasis. It is essential to rule out distant metastases before embarking on potentially morbid treatments.

If PET-CT scanning is not readily available, then, in addition to an examination under anesthetic, the assessment may include serial CT (**Fig. 12.3**) or MRI, comparing the posttreatment scan with the pretreatment scan and/or a baseline posttreatment scan of the primary site.[7,8] This has been shown to improve the accuracy of the detection of primary site recurrences. Further details are provided in Chapter 1.

Examination under Anesthetic

Examination under anesthetic (EUA) is not necessary if the patient has isolated nodal metastases that have been confirmed on needle biopsy and where the primary site has been assessed carefully by clinical examination and detailed imaging, as described above. However, EUA is recommended if only limited assessment of the primary site has been possible, since clinical examination has a low sensitivity in previously treated regions. EUA is also recommended if there is a confirmed primary site recurrence on clinical examination or cross-sectional imaging, as it allows accurate assessment of the primary site extent and potential resectability, and allows samples to be obtained for histological confirmation of the diagnosis.

Needle or Open Biopsy

It is important to obtain a cytological or histological diagnosis of recurrence, as diagnostic imaging investigations often have a low specificity. If a primary site recurrence is present, then histological confirmation can be obtained by biopsy during the examination under anesthetic. Diagnosis in the case of isolated nodal metastases can be obtained by fine-needle biopsy or core biopsy of the neck nodes. It is important that the cytology is examined by head and neck pathologists to decrease the risk of false positives and negatives. If a result cannot be confirmed on needle biopsy, then a diagnosis can be obtained by open biopsy or frozen section. Care should be taken when undertaking the biopsy to plan incisions with potential further surgical treatments in mind.

Management

Recurrence in the Untreated Neck

Surgery with or without Adjuvant Therapy

In patients whose previous treatment did not include neck dissection, the treatment options for nodal recurrence depend predominantly on whether there is also a recurrence at the primary site.

The preferred treatment of an isolated nodal recurrence, if operable, is by a neck dissection.[2] Histopathological examination of the specimens will yield information for making an informed decision on whether adjuvant therapy is necessary in the form of postoperative radiotherapy or chemoradiotherapy.

A recent combined analysis of the results of two large randomized controlled trials examining the efficacy of chemoradiotherapy in the postoperative setting demonstrated that patients with nodal extracapsular extension or involved resection margins were most likely to benefit from the addition of concomitant cisplatin to postoperative radiotherapy. Patients with multiple nodes, lymphovascular invasion, or perineural invasion did not clearly benefit from adding cisplatin to postoperative radiotherapy.[9–11]

Radiotherapy with or without Chemotherapy

In some situations where surgery is not possible, radiotherapy or chemoradiation to the nodal recurrence can be an effective option, particularly when the nodal recurrence is less than 3 cm in maximum size.[12] In modern clinical practice this approach is therefore usually limited to patients of poor performance status or those who are medically inoperable. Brachytherapy, which generally requires anesthesia, is not an option for such patients.

When radiotherapy is given in this context, external beam photon radiation to doses of 65–70 Gy over 6–7 weeks is preferred as it will allow the irradiation of the whole hemi-neck, which is almost always at risk. The indication for elective irradiation of the contralateral neck nodes depends on the site of the primary tumor and the relapse-free interval from previous treatment. Mid-line primary tumors and short relapse-free intervals are generally indications for bilateral radiation.

■ Recurrence in the Previously Treated Neck

Salvage Surgery for Recurrence following Chemoradiotherapy

There is evidence in the literature that surgical salvage of nodal recurrence following radiotherapy or chemoradiotherapy is feasible in a significant number of patients. Overall, it is only successful in controlling the regional disease in approximately 50% of cases. For example, Ord reported a salvage rate of 50% for regional recurrence in their retrospective cohort of 349 oral cancer patients.[2] Homma et al.[13] reported on 27 patients who had persistent or recurrent nodal disease following chemoradiotherapy. Twenty-one patients proceeded to neck dissection, 16 of whom had nodal control. Of the 27 patients, seven had a recurrence after initial remission of N2-N3 nodal disease with chemoradiotherapy. Four of these patients had neck dissection, two of whom achieved regional control. The other three patients refused neck dissection, two of whom died. The remainder of the patients had N1 disease (7 patients) or N2 disease (13 patients) that did not achieve complete response to chemoradiotherapy in the neck. Neck dissection yielded nodal control 4 of the 7 with persistent N1 disease and in 10 of the 13 with persistent N2 nodal disease.

In a series of 65 patients treated with chemoradiotherapy reported by Rengan,[14] nine had nodal recurrence. Neck dissection was performed in four patients and yielded nodal control. Two patients refused further treatment and the remaining three did not undergo salvage because of poor performance status. Lavertu et al. analyzed the results of a phase III trial that randomized 100 patients to radiotherapy or chemoradiotherapy. Of the 50 patients who showed complete response following treatment, 7 had nodal recurrence, of whom 4 had N1 disease and 3 had N2/N3 disease. Long-term salvage was only achieved in one patient who had initial N1 disease.[15]

Salvage Surgery for Recurrence following Previous Neck Dissection

Surgical salvage of nodal recurrence in a previously dissected neck is difficult and less likely to succeed than in a neck previously treated with chemoradiotherapy.[16] This is related to a variety of factors, most importantly the proximity and attachment of recurrent tumor to critical tissues (vessels and nerves) in a fibrotic neck and patients' unwillingness to pursue further salvage surgery with its increased morbidities and functional deficits. Krol et al. found that a previous neck dissection was a negative predictive factor for survival after salvage of nodal recurrence.[16] Wong et al. reported a salvage rate of 56% and 5-year tumor free rate of 32% for unilateral nodal recurrence in a previously undissected neck. In contrast, these rates fell to 32% and 18%, respectively, for nodal recurrence in a previously dissected neck.[17] Jeong et al. also found trends for poorer salvage rates in patients with a recurrence in a previously dissected neck.[4] Unfortunately, there is little data reported on the complication rates of surgical salvage in this setting.

Re-irradiation and Chemotherapy following Surgical Salvage

Intuitively, re-irradiation following failure due to previous radiotherapy is a difficult concept to accept. This is because there is evidence that clonogens surviving initial radiation are likely to be radioresistant.[18] It thus raises the question whether the resultant considerable late complications within the normal tissues can be justified by the potential survival benefit of adding re-irradiation. However, recurrent tumors may still be radiosensitive for a variety of reasons. First, they may represent second primary tumors that were not exposed to previous radiation, and so may be expected still to be sensitive to it. Second, recurrences, especially those at the penumbra of treatment fields, may represent geographic misses of treatment. Finally, some cytotoxic agents may increase radiosensitivity of tumors. In addition, resection or maximal debulking may decrease radioresistant clonogens to a minimum.[18] These issues are discussed in more detail in Chapters 4 and 5.

Re-irradiation and chemotherapy appear to confer a survival and control advantage when given to patients who have undergone macroscopically complete resections of nodal recurrence in a previously treated field. However, selection criteria vary among centers, series are usually small, and reported outcomes are inconsistent. Ord et al. reported achieving the highest salvage rate (70.6%–100%) of regional recurrence in patients who had surgery followed by radiotherapy or chemoradiotherapy compared with surgery alone (28.5%). De Crevoisier et al. reported a pilot study of 25 patients with positive margins or nodal extracapsular extension following macroscopically complete resections for recurrence.[19] The patients received re-irradiation of 60 Gy in alternating weeks and concomitant 5-fluorouracil and hydroxyurea. They reported a 64% 6-month locoregional control and a 36% disease-free survival rate at 2 years. Machtay et al. reported a similar pilot study in 16 patients with locally advanced rT3 or T4 or N+ recurrent disease. Patients received 54–60 Gy split-course radiotherapy and cisplatin, 5-fluorouracil, and amifostine. They reported 2- and 3-year locoregional control rates of 100% and 81%, respectively.[20] The GETTEC and GORTEC groups in France then conducted a randomized trial of 65 patients with recurrence treated with salvage surgery with macroscopic complete resection. Patients were randomized to surveillance or radiotherapy (60 Gy over 11 weeks) with concomitant fluorouracil and hyroxyurea. Disease-free survival was improved in the chemo–re-irradiation arm (odds ratio, 1.68; 95% CI, 1.13–2.50) but there was no statistically significant difference in overall survival. Thus re-irradiation with concomitant chemotherapy appears to confer a locoregional control and disease-specific survival advantage when given to patients who have undergone macroscopically complete resections of nodal recurrence in a previously treated field.

One of the main reasons for the low acceptance of re-irradiation is the concern over acute and late toxicity, which is often considered to be a high price to pay for the relatively low potential cure or benefit. The GETTEC/GORTEC study reported increased

acute and late toxicities in the chemoirradiation arm compared with the surveillance-only arm.[22] However, other studies have not shown increased acute toxicity rates.[20,21] The late toxicity may be considerable and can include cervical fibrosis (up to 44%), soft tissue complications (up to 38%), mucosal necrosis (up to 20%), osteoradionecrosis (up to 16%), and pharyngeal complications and dysphagia (up to 38%). Thus, re-irradiation with chemotherapy should only be offered to carefully selected patients, usually those who have had complete macroscopic resection, after weighing the potential benefit against risks. Patients should be counseled carefully and consent obtained regarding the potential severe complications and the relatively low cure rates.

Unresectable Recurrences

The published series using brachytherapy only for salvage of recurrent neck nodes report a 25% local control rate at 3 months.[22] Bollet et al.[23] report a 31% local control rate at 2 years and only 1% at 5 years, at the risk of a 35% complication rate and a 7% rate of toxic death.

Techniques involving surgical excision and brachytherapy are reported by several authors.[24–26] Punthwala et al.[25] report local control rates of 74% at 6 months and 23% disease-free survival at 5 years with a 27% late complication rate from radiotherapy. Zelefsky et al.[26] report a local control rate of 65% at 1 year, 26% at 2 years, and 20% overall survival at 2 years. A 6% severe complication rate was reported, including a 3% carotid blowout rate. Park et al.[24] reported a disease-free survival rate of 41% at 5 years and a 36% significant complication rate with iodine-125 seed implantation.

Nutting et al. reported in-field local control rates of 40%–62% at 2 years and 40%–58% at 5 years. This figure is higher than that of Zelefsky et al.,[26] which may be due to improved techniques or to more stringent definition of what represents in-field local control versus locoregional control. One of the problems is the difficulty of determining the exact site of recurrence in relation to the brachytherapy dose distribution. Our data show that these local control figures can be maintained out to 5 years, a previously unpublished observation.[3] The data from Park et al.[24] appear to show a much higher rate of disease-free survival than other series. This is probably due to patient selection; in particular not all patients in that series had previously undergone radiation therapy. Furthermore, the lack of pathological data as to the incidence of macroscopic residual disease after resection makes comparison between series difficult.

In our series of 72 patients, we have demonstrated that surgical excision (even if subtotal), reconstruction, and low-dose-rate brachytherapy to the tumor bed offers a reasonable chance of achieving local control and even prolonged disease-free interval in the absence of a significant risk of serious toxicity. The overall major complication rates compares favorably with other series, and is a reflection of the degree of previous therapy received by this patient group.

Initial experiences with direct insertion of brachytherapy wires into bulky residual tumor masses without attempting tumor debulking were disappointing, with no patient achieving locoregional control at 2 years. Potential explanations for this finding include the suboptimal radiation dosimetry achieved with this approach, the failure to reduce the density of radiation-resistant clonogens, and the toxicity of treatment to normal tissues.

Patient Selection and Risk Factors for Poor Outcomes after Salvage

Patient and Tumor Features

The number and size of the nodal recurrence (larger than 3 cm) may predispose to a higher failure rate.[4] Recurrence in a previously dissected neck is associated with a poorer treatment outcome,[2,4] as is a history of a previous local recurrence before the regional recurrence.[4] Furthermore, some studies appear to suggest that initial N1 disease may be more amenable to control if the nodal disease fails to respond,[16] while others do not show the same finding.[15]

Treatment Factors

Combined treatment of the nodal recurrence by surgery and radiotherapy, with or without chemotherapy, results in better control rates.[2,20,21] It should also be noted that patients with extranodal extension or positive margins after neck dissection have a higher risk of failure after neck dissection.[15,27]

Special Considerations

Surgery

Type of Neck Dissection

Traditionally, surgical treatment of nodal recurrence was considered to necessitate a radical neck dissection, or at least a modified radical neck dissection. This would include all five nodal levels, even if they were not all involved by recurrence. However, the morbidity of a level V neck dissection has encouraged further examination of this principle. Level V nodal involvement is uncommon even in the recurrent situation. More recently, a more selective approach to neck dissection for nodal recurrence has emerged. A prospective study showed that in persistent nodal disease following chemoradiotherapy setting, only 2 out 54 necks had disease in more than one nodal level.[28] Another study from the same group prospectively examined the nodal recurrence rates following 106 neck dissections in 84 patients with bulky nodal recurrence after chemoradiotherapy. They reported a 17% (2 of 17) regional failure rate in patients who had modified radical neck dissections, compared with 5% (3 of 65) regional failure rate in patients having selective neck dissection. They also reported on a small series of 7 superselective neck dissections—where only the nodal levels that were involved and those that were immediately next to them were removed. There were no recurrences in that group.[29]

Van der Putten et al.[30] reported on a series of 68 neck dissections in 61 patients with suspected nodal recurrence after chemoradiotherapy, 26 of whom had confirmed tumor on neck dissection. Half of the patients had a selective neck dissection and half had a modified radical neck dissection. Four developed regional recurrence in the dissected neck, with no difference in incidence between patients who had selective and modified neck dissections.

Stenson reported on a retrospective cohort of 69 patients with advanced stage III and IV head and neck cancer who received chemoradiotherapy and had posttreatment selective neck dis-

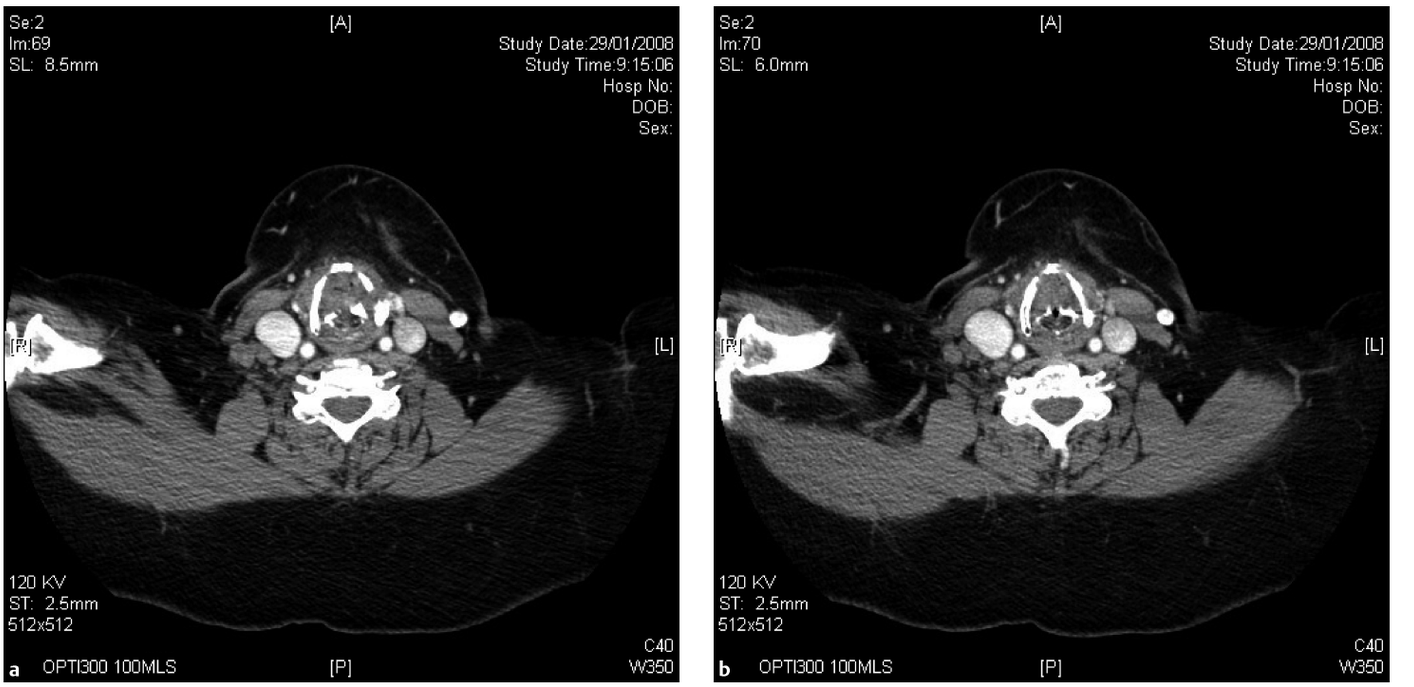

Fig. 12.4a, b Nodal recurrence behind the jugular vein following treatment for supraglottic carcinoma.

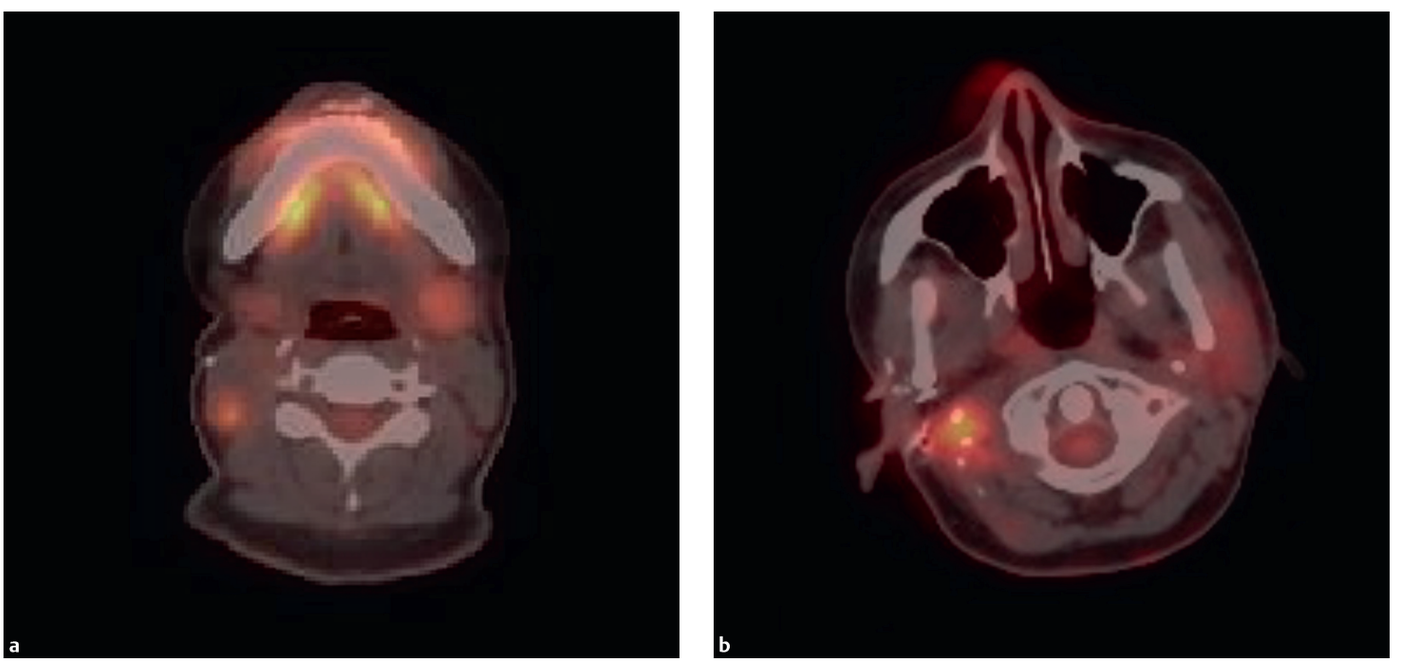

Fig. 12.5a, b PET-CT scans showing multiple recurrent nodes in the neck (**a**) and in the parotid bed (**b**).

sections. Of those, only one recurred in the neck.[31] These studies therefore support selective neck dissection as a viable option for the treatment of nodal recurrence. Care should be exercised in extrapolating these data as the studies are mainly retrospective cohort studies, and therefore patient selection criteria might affect the overall outcome.

Case Study

A 69-year-old woman presented with hoarseness. She was found to have a T3N1 supraglottic squamous cell carcinoma, with a metastatic lymph node in level III on the right (1.5 cm in cross-sectional diameter with suspicious features on contrast CT scanning). She received primary radical concomitant chemoradiotherapy—70 Gy in 35 fractions with two doses of concomitant cisplatin (100 mg/m^2). Three months after the end of chemoradiotherapy, the patient had a PET-CT scan that showed no evidence of persistent disease. The patient received out-patient monthly follow-up according to the institution's protocol. Eighteen months later, the patient complained of increased breathlessness. Flexible nasendoscopy showed edema of the supraglottis but no evidence of local recurrence.

A contrast CT scan confirmed supraglottic edema, but also detected two suspicious lymph nodes (12 mm and 8 mm in

cross-sectional diameter) in level III on the right side (**Fig. 12.4**). The CT scan of her chest was clear. US-guided needle aspiration was performed, which confirmed metastatic squamous carcinoma. A panendoscopy confirmed that there was no recurrence in the larynx.

We recommended that the patient have a selective right neck dissection (levels II–V). Seventeen nodes were identified on histopathological examination of the specimen, of which one (20 mm maximum diameter) was involved with metastatic tumor, with extranodal extension. Adjuvant chemo–re-irradiation was discussed with the patient, who declined the treatment. Disease control was achieved in the neck for a further 20 months, when the patient developed a second primary non–small cell lung carcinoma with metastasis. She is undergoing palliative treatment and is still alive.

Special Considerations

- If this patient presented now, we would perform a PET-CT scan to exclude locoregional and distant metastasis, instead of a CT scan.
- The patient is also counseled about the higher risk of spinal accessory nerve sacrifice during her operation, as well as the usual risks of the operation.
- The patient was offered chemo–re-irradiation of the neck following surgery. She was counseled about the possible complications, including late complications of irradiation. She declined.

Case Study

A 28-year-old patient presents with parotid lump which is removed in a local hospital. The histology is an epithelial-myoepithelial carcinoma of parotid. She has no clinically evident nodal disease on examination or contrast CT scan or MRI. A local recurrence is identified 18 months after her first operation, with no evidence of regional recurrence. She undergoes a further MRI scan of the head and neck, as well as CT scan of the neck and chest. This confirms a local recurrence in the parotid with extraparotid extension and no nodal or distant metastases. Fine-needle aspiration confirms recurrent carcinoma. We review her initial histology and confirm the diagnosis. She therefore undergoes a second operation to have a total parotidectomy, and resection of the mastoid tip and sampling of the level II nodes—which were clear on frozen section. On histological examination, she has a large recurrence with extraparotid extension with clear margins and grade 2 facial nerve function. The seven level II nodes were clear on histology. Due to the size of the recurrence, extraparotid spread, and the intermediate histology with rapid recurrence suggesting an aggressive course, she has radiotherapy of 55 Gy to the parotid bed including some of level II of the neck.

She undergoes a further MRI scan of the head and neck, as well as CT scan of the neck and chest. This confirmed many abnormal lymph nodes in the neck in all five levels. There is no recurrence at the primary site. She also has a PET-CT scan which shows no distant metastases (**Fig. 12.5**).

We recommended that the patient have a completion neck dissection ± re-irradiation. We explained to the patient that she would have a modified radical neck dissection with likely sacrifice of the internal jugular vein and sternomastoid muscle. We also explained that it is highly likely that we may need to convert the procedure to a radical neck dissection with sacrifice of the spinal accessory nerve, and its resultant morbidities.

At the operation, the spinal accessory nerve was preserved, but the sternomastoid muscle and internal jugular vein were sacrificed. Fifty-eight nodes were removed, of which 48 are involved with metastatic tumor, with extranodal extension and soft tissue deposits. We have recommended that she has postoperative irradiation to the nodal bed, which would include re-irradiation of level II nodes. As the histology was epithelial carcinoma of the parotid, there is no evidence to support the addition of chemotherapy. The patient has recently undergone re-irradiation, and experienced acute skin toxicities. This has settled, leaving her with pigmentation of her skin, but no other side-effects.

Special Considerations

- The patient was counseled about the higher risk of spinal accessory nerve sacrifice during her operation, as well as the usual risks of the operation.
- The patient is 30 years old. As she was going to have re-irradiation of the neck she was counseled about the possible complications, including late complications of irradiation. She was also counseled about the small risk of secondary sarcomas in future.

Incisions

Due to the poor vascularity of the skin in patients following chemoradiotherapy, one should consider avoiding any three-point junctions, especially over the carotid sheath and level V. The use of single mid-neck horizontal incision or the McFee incisions provides more than adequate exposure if a neck dissection is required. It can also be extended medially into a lip split incision if required. For the combined surgical treatment of laryngeal and nodal recurrences, a U-shaped utility incision is usually adequate.

In situations where there is difficulty closing the skin following surgery, consideration should be given to the use of a pedicled flap, such as a pectoralis major myocutaneous flap with skin paddle, or a fasciocutaneous free flap, such as free radial forearm flap. This reduces the tension on the skin flaps and is likely to decrease the risk of devascularization and wound dehiscence.

Carotid Encasement

Resection of the tumor may be difficult in situations where the carotid is in contact with the recurrent tumor. This is especially the situation when there has been previous surgery or radiotherapy, due to reactive fibrosis, which causes obliteration and loss of the natural planes. In these cases, it is wise to secure control of the carotid vessels above and below the area concerned so that if there is a breach of the vessel wall, control of the hemorrhage can be achieved while repair can be performed.

Gross complete resection of the tumor becomes increasingly difficult when the tumor is in contact with the carotid artery over more than 180° of its circumference. It is widely accepted that when the tumor is in contact over 270° of the circumference, removal

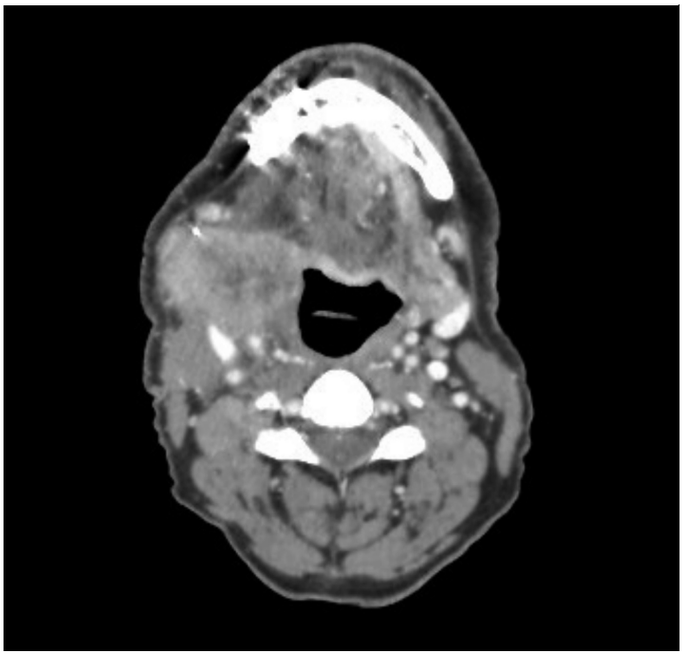

Fig. 12.6 Carotid encasement by massive lymphadenopathy.

without breaching the tumor is not usually possible (**Fig. 12.6**). In that case, the only other option is ligation and resection of the carotid, with either no reconstruction or reconstruction using an interposition graft (usually either saphenous vein or a synthetic graft). This procedure requires the input of a vascular surgeon and can carry significant potential morbidity in the form of cerebrovascular accidents and death. Furthermore, outcomes of tumor control and survival following carotid resection are very poor.

A meta-analysis of carotid resection for head and neck cancers, including 158 patients, from 22 articles, revealed that 35% of patients had ligation and 65% had reconstruction, mainly with autologous vein. The overall rate of neurological complications was 26%, of which 16.7% were major cerebrovascular accidents and 10.7% were mild pareses. There was no difference in the risk of cerebrovascular accident between the patients who had a ligation and those who had reconstruction of the carotid. The overall 2-year recurrence rate was 74%: 32% local, 47% regional, and 21% distant recurrence. The overall 2-year disease-free survival rate was 22%, which was lower than in a control group that did not have carotid artery resection. It should be noted that these outcomes included both primary and recurrent patient groups.[32] Biller et al. reported on 25 patients with recurrent head and neck cancer treated with carotid resection and reconstruction. Neurological sequelae were seen in 7% of patients and the 1-year disease-free survival rate was only 25%.[33] Therefore, carotid artery resection and reconstruction in the recurrent setting should only be performed in highly selected patients, with careful assessment and counseling on potential complications and on possible benefits and outcomes.

Assessment Prior to Carotid Resection

Initial assessment is by magnetic resonance angiography (MRA) of the cerebral circulation to see whether there are any collaterals between the two circulations. Importantly, conventional angiography with awake temporary balloon occlusion should be performed to assess the patient's cognitive and neurological function while the balloon is occluded for 10 minutes. In addition, distal carotid stump pressure measurements can be made. High stump pressures during occlusion signify a good collateral circulation and a low risk of neurological sequelae. Finally some centers perform single-photon emission computed tomography (SPECT) during balloon occlusion, which demonstrates the cerebral function during occlusion (**Fig. 12.7**). Others use intraoperative transcranial Doppler to monitor cerebral circulation intraoperatively in response to temporary clamping of the carotid artery.

Radiation with or without Chemotherapy

Patients who have not received previous neck irradiation presenting with isolated recurrence in a single node, measuring less than 3 cm without extranodal extension, can be observed after neck dissection. Adjuvant radiotherapy is only indicated when multiple nodes are involved and, in patient who are medically fit, concurrent cisplatin is recommended in the presence of extranodal extension or positive margins. The radiation doses are typically 60–66 Gy to the positive nodal basin and 50–54 Gy to the remaining uninvolved ipsilateral lymphatics given in single daily fractions of 2 Gy over 6–6.5 weeks. When nodal relapse occurs in less than 1 year from initial treatment of the primary tumor, it might be reasonable to include the primary tumor bed and, when the index cancer is situated at or near mid-line, and also to include the uninvolved contralateral neck nodes.

The indications and technique of radiotherapy for patients who have recurrence after previous radiation with or without chemotherapy are presented in more detail in Chapter 4. Briefly, postoperative re-irradiation can yield long-term disease control and survival in carefully select patients. The target volume should be kept as small as possible, for example, only ipsilateral lymphatics for those with isolated nodal recurrence, to minimize complications. The radiation dose is limited to 56–60 Gy in daily 2 Gy fractions and cisplatin is added concurrently in patients with high-risk pathological features such as extracapsular spread or positive margins. The use of intensity-modulated radiation therapy is beneficial for conforming radiation to the high-risk tissues while sparing as much of normal organs as possible. Re-irradiation with intraoperative brachytherapy can be considered in very selected cases but this should be performed by an experienced radiation oncologist.

Selected nodal relapse that is not amenable to neck dissection can be treated with re-irradiation combined with chemotherapy. In the re-irradiation setting, the dose is generally kept at 60 Gy in 30 fractions.

Outcomes

Salvage surgery following recurrence after radiotherapy and chemoradiotherapy is successful in approximately 50% of patients, as reported by several studies detailed above. There is, however, little data on the actual survival outcomes of such patients. Wong for example reported a 5-year tumor-free rate of 32%.[17] Overall survival is often much lower than successful salvage rates due to

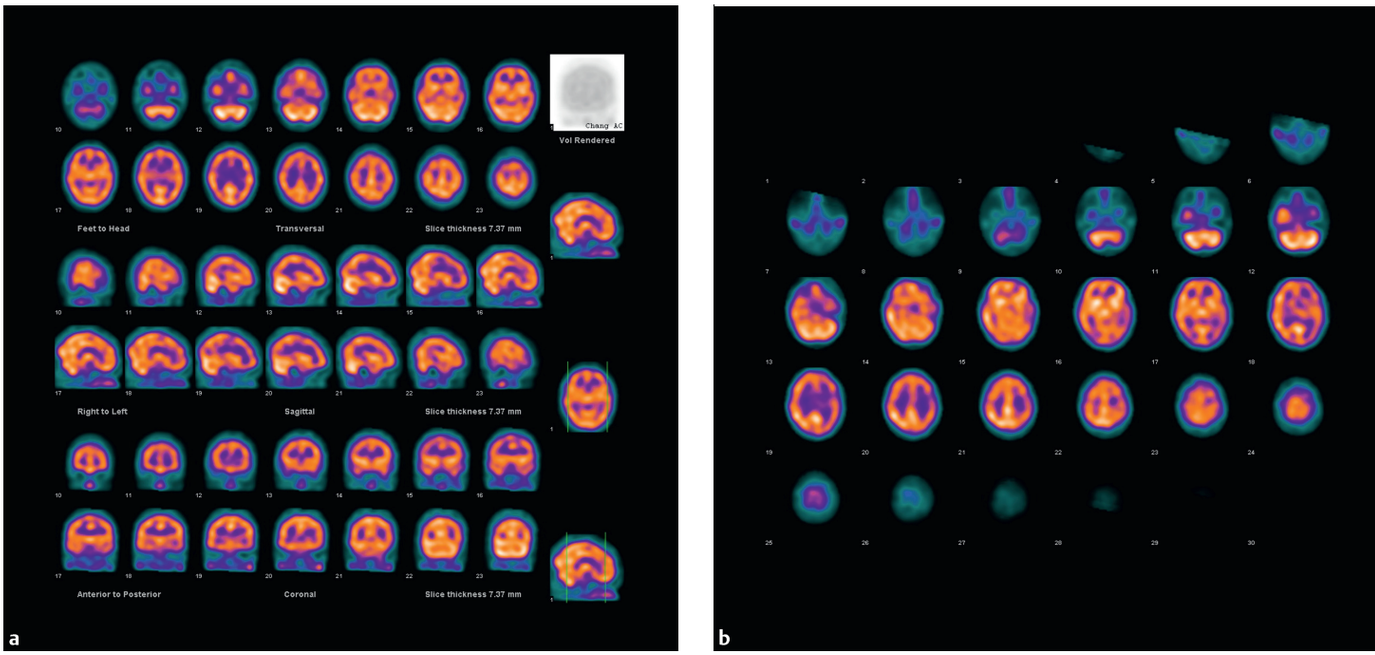

Fig. 12.7a, b Normal (**a**) and abnormal SPECT activity (**b**) in the brain.

death from primary recurrence, distant metastases, and other intercurrent illnesses.

Recurrence following previous neck dissection carries a poor prognosis whether patients were also treated with chemoradiotherapy or not (**Fig. 12.8**). Krol et al. found that a previous neck dissection was a negative predictive factor for survival after salvage of nodal recurrence.[16] In the series reported by Wong, 5-year tumor-free survival fell to 18% for nodal recurrence in a previously dissected neck.[17]

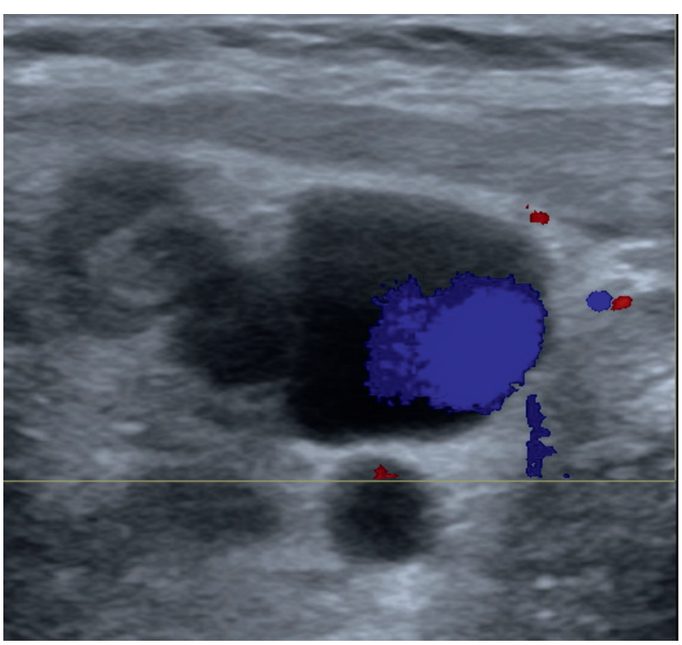

Fig. 12.8 Nodal recurrence—enhancing on scan—in a previously dissected neck carries a poor prognosis.

Complication Rates

Surgery

Complication rates for neck dissection in the recurrent setting are very poorly reported. Intuitively, however, it is likely that complication rates following salvage surgery may be higher if previous treatment had taken place. Indeed, Lin et al. found that the 53 patients treated for recurrence had higher rate of complications (60.7%) compared with 135 previously untreated patients (30.4%). However, they found no difference in *major* complication rates between the two groups.[34] Lavertu reported retrospectively on a cohort of 30 patients who had salvage neck dissection for recurrence after radiotherapy or chemoradiotherapy compared with 29 who had planned neck dissections. There was a significantly increased complication rate in patients who had salvage procedures compared with those who had planned neck dissections (60% vs. 31%, $P = 0.04$). Overall, 60% of patients having salvage neck dissection had complications. Of those, 6 (20%) had a major complication including carotid artery rupture, pharyngocutaneous fistula, sepsis, cerebrovascular accident, bleeding duodenal ulcer, and pharyngeal stenosis; 12 (40%) had minor complications including skin incision breakdown, partial small-bowel obstruction, and granulation at tracheostomy. There were no differences in either major or minor complication rates between patients who had radiotherapy and those who had chemradiotherapy.[35]

Re-irradiation

Patients treated successfully with re-irradiation risk long-term permanent side effects. Late complications can affect any of the tissues in the neck including skin, subcutaneous tissues, muscle, nerves, bone, thyroid gland, and spinal cord. Overall, severe late radiation complications are seen in approximately 25.7% of patients

who are treated by re-irradiation. Higher rates of normal tissue damage are seen in patients treated with chemoradiation.

Radionecrosis of the skin is occasionally seen and is usually precipitated by trauma. Late radiotherapy effects of the skin, muscles, and other tissues leads to scarring, fibrosis, and stiffness of the neck. Hypothyroidism is common after re-irradiation of the low neck and should be biochemically screened for in this patient group. Clinically, damage to the phrenic, vagus, and hypoglossal nerves is rare. Avoidance of re-irradiation of the spinal cord and the mandible is critical to avoid damage to these organs. Lethal carotid hemorrhage is seen in 3%.[36] Refer to Chapter 4 for more details.

Future Research

- Predictive biomarker for propensity of nodal spread to identify patients for aggressive elective therapy to minimize nodal relapse.
- Role of surgical debulking before chemotherapy and re-irradiation in patients where resection cannot achieve complete gross clearance.
- Functional and quality of life outcomes following the different treatments for recurrent nodal disease.
- The role of targeted agents in the treatment of nodal recurrence to improve therapeutic ratio.

Recommended Reading

- Creak AL, Harrington K, Nutting C. Treatment of recurrent head and neck cancer: re-irradiation or chemotherapy? Clin Oncol (R Coll Radiol) 2005;17(3):138–147. (Good review on treatment of recurrent head and neck cancer by re-irradiation.)
- Ord RA, Kolokythas A, Reynolds MA. Surgical salvage for local and regional recurrence in oral cancer. J Oral Maxillofac Surg 2006;64(9):1409–1414. (Good study on surgical salvage in local and regional recurrence in oral cancer.)
- Salama JK, Vokes EE. Concurrent chemotherapy and re-irradiation for locoregionally recurrent head and neck cancer. Semin Oncol 2008;35(3):251–261. (Good review on treatment of recurrent head and neck cancer by re-irradiation and chemotherapy.)
- Isles MG, McConkey C, Mehanna HM. A systematic review and meta-analysis of the role of positron emission tomography in the follow up of head and neck squamous cell carcinoma following radiotherapy or chemoradiotherapy. Clin Otolaryngol 2008;33(3):210–222. (Review of accuracy of PET-CT in the detection of regional recurrence.)

References

1. Ridge JA. Squamous cancer of the head and neck: surgical treatment of local and regional recurrence. Semin Oncol 1993;20(5):419–429
2. Ord RA, Kolokythas A, Reynolds MA. Surgical salvage for local and regional recurrence in oral cancer. J Oral Maxillofac Surg 2006;64(9):1409–1414
3. Nutting C, Horlock N, A'Hern R, et al. Manually after-loaded ^{192}Ir low-dose rate brachytherapy after subtotal excision and flap reconstruction of recurrent cervical lymphadenopathy from head and neck cancer. Radiother Oncol 2006;80(1):39–42
4. Jeong WJ, Jung YH, Kwon SK, et al. Role of surgical salvage for regional recurrence in laryngeal cancer. Laryngoscope 2007;117(1):74–77
5. Isles MG, McConkey C, Mehanna HM. A systematic review and meta-analysis of the role of positron emission tomography in the follow up of head and neck squamous cell carcinoma following radiotherapy or chemoradiotherapy. Clin Otolaryngol 2008;33(3):210–222
6. Kao J, Vu HL, Genden EM, et al. The diagnostic and prognostic utility of positron emission tomography/computed tomography-based follow-up after radiotherapy for head and neck cancer. Cancer 2009;115(19):4586–4594
7. van den Broek GB, Rasch CR, Pameijer FA, Peter E, van den Brekel MW, Balm AJ. Response measurement after intraarterial chemoradiation in advanced head and neck carcinoma: magnetic resonance imaging and evaluation under general anesthesia? Cancer 2006;106(8):1722–1729
8. Hermans R, Pameijer FA, Mancuso AA, Parsons JT, Mendenhall WM. Laryngeal or hypopharyngeal squamous cell carcinoma: can follow-up CT after definitive radiation therapy be used to detect local failure earlier than clinical examination alone? Radiology 2000;214(3):683–687
9. Bernier J, Domenge C, Ozsahin M, et al. European Organization for Research and Treatment of Cancer Trial 22931. Postoperative irradiation with or without concomitant chemotherapy for locally advanced head and neck cancer. N Engl J Med 2004;350(19):1945–1952
10. Cooper JS, Pajak TF, Forastiere AA, et al. Radiation Therapy Oncology Group 9501/Intergroup. Postoperative concurrent radiotherapy and chemotherapy for high-risk squamous-cell carcinoma of the head and neck. N Engl J Med 2004;350(19):1937–1944
11. Bernier J, Cooper JS, Pajak TF, et al. Defining risk levels in locally advanced head and neck cancers: a comparative analysis of concurrent postoperative radiation plus chemotherapy trials of the EORTC (#22931) and RTOG (# 9501). Head Neck 2005;27(10):843–850
12. Brizel DM, Prosnitz RG, Hunter S, et al. Necessity for adjuvant neck dissection in setting of concurrent chemoradiation for advanced head-and-neck cancer. Int J Radiat Oncol Biol Phys 2004;58(5):1418–1423
13. Homma A, Furuta Y, Oridate N, et al. "Watch-and-see" policy for the clinically positive neck in head and neck cancer treated with chemoradiotherapy. Int J Clin Oncol 2006;11(6):441–448
14. Rengan R, Pfister DG, Lee NY, et al. Long-term neck control rates after complete response to chemoradiation in patients with advanced head and neck cancer. Am J Clin Oncol 2008;31(5):465–469
15. Lavertu P, Adelstein DJ, Saxton JP, et al. Management of the neck in a randomized trial comparing concurrent chemotherapy and radiotherapy with radiotherapy alone in resectable stage III and IV squamous cell head and neck cancer. Head Neck 1997;19(7):559–566
16. Krol BJ, Righi PD, Paydarfar JA, et al. Factors related to outcome of salvage therapy for isolated cervical recurrence of squamous cell carcinoma in the previously treated neck: a multi-institutional study. Otolaryngol Head Neck Surg 2000;123(4):368–376