7 Full-Endoscopic Lumbar Diskectomy for Migrated Lumbar Disk Herniation

Marcus Vinicius Flores de Barros Vasconcelos Fernandes Serra

7.1 Disease Profile

Lumbar disk herniations are common pathologies and are associated with significant adverse health effects for patients who experience them. Migration of a lumbar disk fragment refers to its cranial or caudal displacement from the original disk space. According to preoperative magnetic resonance imaging (MRI) findings, disk migration was classified into four zones based on the direction and distance from the disk space: zone 1 (far up), zone 2 (near up), zone 3 (near down), and zone 4 (far down).[1] This migration can be classified as cranial or caudal, and its occurrence increases the technical demand for resection. However, it is important to note that sequestrations, often resulting from migration, are associated with rapid reabsorption and symptom improvement, which can sometimes reduce the need for surgery. On the other hand, migrations are related to a higher likelihood of the patient presenting with motor deficits and cauda equina syndrome.

7.2 News

Historically, microdiskectomy was the gold standard for treating central, posterolateral, and even foraminal disk herniations, with the Wiltse approach being an option for extraforaminal herniations. However, with the advent of endoscopy—from Kambin to Hishikata[2] to modern times—spinal endoscopy has demonstrated superior outcomes compared to microdiskectomy. This culminated in a publication in the *Global Spine Journal*,[3] where endoscopy was identified as the new gold standard in the treatment of disk herniations, based on evaluations of both primary and secondary outcomes.

7.3 Synonyms

Transforaminal endoscopic access, outside-in technique, TFFP: transforaminal with foraminoplasty

7.4 Keywords

Migrated hernia, classification for migrated hernias, superior articular process, foraminoplasty, and pediculectomy for down-migrated disk herniation

7.5 Definition

Transforaminal endoscopic lumbar diskectomy (TELD) and transforaminal endoscopic lumbar foraminotomy (TELF)[4] are minimally invasive procedures that can address lumbar disk pathologies regardless of their location using the outside-in technique. In these techniques, a puncture is performed at the junction of the pedicle with the facet (superior articular process [SAP]), followed by the introduction of a dilator, a working sleeve, and, finally, an endoscope. Depending on the location (foraminal or extraforaminal) and utilizing navigation concepts, the exiting nerve root and disk fragment can be identified and resected. In cases of centrally or posterolaterally migrated hernias, and depending on the degree of migration, foraminoplasty (drilling of the SAP) and pediculectomy (Sang Ho Lee 4 [SHL 4]) should precede identification of the nerve root, disk, and diskectomy. The procedure concludes when the observed nerve root is loose and floating under direct visualization.

7.6 Classification of the Technique Compared to Other Procedures

- For years, the inside-out technique (half and half)[5] has been used to resect these fragments, especially when they were classified as SHL 2 and 3, reserving foraminoplasty for cases of high-grade caudal migration (associated with pediculectomy) and even for cranial migrations (SHL 1) if they occurred centrally or posterolaterally.[1]
- The indications for the TELD outside-in approach have expanded due to the reduction[2] in cases of postoperative dysesthesia.[6] It is important to remember that in central or posterolateral hernias, foraminoplasty should be considered, and if there is a caudal migration, a pediculectomy is necessary.

from: Kim et al,Video Atlas of Endoscopic Spine Surgery and Procedures (9781684207053)
© 2026. Thieme. All rights reserved.

- For foraminal hernias (without associated foraminal stenosis) and extraforaminal hernias, the approach is not transforaminal. Instead, a posterolateral approach as described by Lübbers et al[7] or an extraforaminal approach as described by Ruetten is preferred[8] in foraminal and extraforaminal hernias that do not pass through the foramen.
- Migrated hernias are associated with a higher chance of recurrence or insufficient resection, according to an article published by Choi et al.[9]

7.7 Indications

Endoscopic surgery should be planned by correlating the patient's clinical presentation with the question of which root is causing pain, followed by determining where the compression site is located and the consistency of the compressing material. For this purpose, classifications are used[10] based on location (central, posterolateral, foraminal, and extraforaminal), migration (SHL 1, 2, 3, and 4), and type of hernia (protrusion, bulging, and sequestration).

Navigation concepts,[11] that is, understanding the anatomy through video, have been incorporated to make the surgery safer. This includes the following:

- The positioning of the forceps, which in the case of migrated hernias will be cranial or caudal in relation to the patient's anatomy.
- The triangulation (already performed by the forceps), which consists of creating an obliquity between the lens and the forceps to visualize where you are working.
- The joystick maneuveris always performed in the opposite direction to where the hernia is located.
- Open the forceps toward the pathology.
- Perform triangulation with the forceps or the endoscope.
- Execute the joystick maneuver to the opposite side of the pathology.

The ideal approach may vary depending on the location of the pathology and the root we want to decompress (▶ Table 7.1).

7.8 Preparatory Diagnostics

- The Michigan State University (MSU) and Janes classifications are used for locating the hernia in the mid-lateral axial plane, with classification into five zones from anterior to posterior,[7] while the SHL classification is used for the sagittal plane.[12]
- In HORUS or any imaging software, axial T2-weighted images are used at the disk level. For central or posterolateral hernias (recess), the target is zone 5 (Z5); for foraminal or extraforaminal hernias, the target is zone 3 (Z3).
- A line is drawn from anterior to posterior through the spinous process and another from the defined target to exit through the skin, ensuring the trajectory avoids the retroperitoneum and stays adjacent to the SAP of the lower vertebra. Measure the distance between the lines; this determines the entry point on the skin, and the sine of the triangle formed determines the puncture angle.
- For foraminal and extraforaminal hernias, the entry point should be between 4 and 8 cm,

Table 7.1 Approaches for pathologies localization

Location	Traversing an existing root	Approach
Central	Transient	Foraminoplasty
Posterolateral	Transient	Foraminoplasty
Foraminal	Emergent	Directly on the hernia
Extraforaminal	Emergent	Directly on the hernia
Cranial migration/foraminal	Emergent	Directly on the hernia
Cranial migration recess	Transient/emergent	Foraminoplasty
Caudal migration	Transient	Foraminoplasty/pediculectomy

from: Kim et al,Video Atlas of Endoscopic Spine Surgery and Procedures (9781684207053)
© 2026. Thieme. All rights reserved.

whereas for central hernias, it should be between 8 and 12 cm. The standard entry point is typically at 10 cm with a 45-degree inclination angle.

7.9 Anesthesia

- Endoscopic surgery via the transforaminal approach has traditionally been performed for many years using local anesthesia with sedation, also referred to as awake and aware surgery.
- Our preference, however, is for general anesthesia, reserving awake surgery as an option in cases of reoperation via the transforaminal approach, particularly when there is a change in the configuration of the safety triangle.[13]

7.10 Personnel, Material, and Adjustment Technology

- 30-degree endoscope (Elliquence).
- Bipolar Trigger-Flex forceps.
- SGT (Surgitech) microdebridement cannula.

7.11 Preparation

- The patient is placed in the prone position, with padding under the chest and shoulder.
- *Operating room setup:* The surgeon and the instrument handler are on the side of the pathology, with the assistant on the opposite side at the head projection of the radioscopic screen, C-arm below the patient, and video tower near the patient's lower limbs.
- *Asepsis and antisepsis and placement of surgical drapes:* Remember to place the upper drape to the side and the lateral drape above to ensure radiation protection during lateral X-rays.

7.12 Anatomy

- Endoscopic spinal surgery (ESS) has provided a new way to understand and visualize the anatomy of the spine. While ESS decreases the surgeon's field of view, it improves visualization by bringing the anatomical perspective into the patient's body and moving the visualization and light source closer to the surgical site. To effectively navigate this limited view, surgeons must focus on key anatomical landmarks, including the exiting nerve roots and their foramina, the SAP, the ligamentum flavum, and the epidural space.
- During the learning phase of ESS, the less experienced surgeon will require more intraoperative imaging to reliably identify these key structures and, consequently, greater exposure to radiation for safer and more effective navigation. With that in mind, we have developed a practical and didactic teaching method based on anatomy for ESS, emphasizing the consistent recognition of these critical landmarks.
- When we are on the left side in a transforaminal approach, the traversing nerve root will be from the 10 o'clock to the 2 o'clock position, the exiting nerve root will be from the 9 o'clock to the 6 o'clock position, and the pedicle will be at the 3 o'clock position. When we are on the right side, the traversing nerve root will be from the 2 o'clock to the 10 o'clock position, the exiting nerve root will be from the 3 o'clock to the 6 o'clock position, and the pedicle will be at the 9 o'clock position. Remember that the traversing will be hidden by the SAP (upper articular process).

7.13 Implementation

- The outside-in transforaminal endoscopic technique for migrated lumbar disc herniation is demonstrated in Video 7.1.
- The outside-in transforaminal endoscopic technique for a down-migrated lumbar disc herniation at L1–L2 is demonstrated in Video 7.2.
- The outside-in transforaminal endoscopic technique for a high-migrated lumbar disc herniation at L4–L5 is demonstrated in Video 7.3.

7.13.1 Lines Drawing

1. With anteroposterior (AP) fluoroscopy, mark a line passing over other spinous processes.
2. Mark a line parallel to the superior endplate of the lower vertebra. This line serves two purposes. First, in planning, the distance from the entry point on the axial T2-weighted image of the disk level is calculated (HORUS); the centimeters on this midline are marked for entry. We calculate the entry point using T2-weighted images in the axial plane at the disk level: the line leaving the disk control, passing through the prickly process, and

from: Kim et al,Video Atlas of Endoscopic Spine Surgery and Procedures (9781684207053)
© 2026. Thieme. All rights reserved.

leaving the skin, and the line leaving the center of the disk passing between the retroperitoneal and the facet and coming out on the skin. The distance between these two lines and the distance from the entry point should be marked on the skin. Second, during the lateral fluoroscopic view, aligning along this line provides an absolute profile. Remember that the target is the junction of the pedicle with the facet, which is why guidance is always based on the superior endplate of the lower vertebra. It is not necessarily the perfect AP view.

3. On lateral fluoroscopy, along the axis of the disk line in the AP view, mark a line parallel to the superior endplate of the lower vertebra.
4. The entry point will be on the lateral line, but the centimeter markings from the AP line need to be transferred to the lateral line. On the AP line, orthogonally project the centimeters onto the lateral line.

7.13.2 Puncture

If entering above the profile line, the trajectory remains parallel to the disk. However, for targeting caudally migrated hernias or performing a pediculectomy, the entry should be above this line; for cranial hernias, the entry should be below this line.

For highly cranially migrated hernias (SHL 1), enter below the profile line; for caudally migrated hernias (SHL 4), enter above the line with an angle greater than 10 degrees.

1. Perform the puncture with lateral fluoroscopy; those accustomed to AP puncture will have no problem since the target remains the same: junction of the pedicle X facet. Insert the needle just above the profile line until the bone structure is felt, and perform an X-ray. In the lateral view, ensure the needle is in the facet line (for those who perform an AP puncture at the lateral pedicular line).
2. With AP fluoroscopy, the position should be at the lateral pedicular line.
3. Pass the nitinol wire and remove the needle.
4. Make a 7-mm skin incision and remember to open the iliolumbar fascia.
5. Insert the dilator.
6. Insert the working sleeve with its rounded tip toward the pedicle. X-ray in the lateral view at the facet line and in the AP view at the pedicular lateral line.

Note

Puncture of the disk in its lower third is feasible; remove the needle and retain the wire in the disk to introduce the endoscope by pivoting the wire (the wire will remain within the endoscope's working area). Entering with the bipolar and delicate tools alongside the wire is also possible.

7.13.3 Full Endoscopy

Navigation and Localization

1. Maintain the endoscope in a neutral position—perpendicular to the patient. In this position, the patient's anatomy will match the video anatomy.
   a) *Left:* The traversing root will be from the 10 o'clock to the 2 o'clock position and the exiting root will be from the 9 o'clock to the 6 o'clock position.
   b) *Right:* Traversing from the 2 o'clock to the 10 o'clock position and exiting from the 3 o'clock to the 6 o'clock position.
   Throughout the surgery, the navigation principles should be adhered to: positioning of instruments, triangulation, and joystick. Positioning the clamp involves rotating the hand in the direction of the pathology on the patient's anatomy clock: for a hernia with cranial migration, rotate the hand cranially. Triangulation involves creating an angle between the clamp and the lens to visualize the working area. When the clamp is positioned medially or laterally, triangulation is done with the endoscope, and when it is positioned cranially or caudally, it is already aligned by the clamp. The joystick is a movement performed with the entire endoscope; whenever moving it to a specific side, adjust your hand to the opposite side. When managing a hernia with cranial migration, use a hand-to-peak approach.
2. When introducing the endoscope, observe the musculature, and it is imperative to clean the facet using a Love punch and bipolar (macro 30 or turbo Surgi-Max). The cleaner the bone, the less dirty the drilling will be.
3. Identify the "J" point, the junction of the pedicle with the facet.

from: Kim et al,Video Atlas of Endoscopic Spine Surgery and Procedures (9781684207053)
© 2026. Thieme. All rights reserved.

4. With the bipolar, burn adjacent to the nitinol wire to identify the disk. At this moment, take care not to enter the foramen; the lateral pedicular line in the AP view must be maintained.
5. After dissecting and exposing the bone structures, remove the nitinol wire.

Drilling and Diskectomy

a) Foraminal/extraforaminal hernias with cranial migration:
   1. Identify the pedicle and rotate the endoscope until the emerging nerve root is found.
   2. Leave the working sleeve bezel rotated toward the pedicle and in a more superficial plane. Visualize the emergent root (direct root visualization [DRV]).
   3. Dissect with a hook from the axilla to the extraforaminal region.
   4. Position the forceps cranially in the patient's anatomical clock; triangulation will be done by the forceps; place your hand toward the foot to locate the fragment (▶ Table 7.2).
   5. First, identify the disk fragment; dissect it using bipolar, hooks, and love forceps; and remove the fragment. Position the hand laterally and cranially, triangulating with the forceps, and perform joystick movements downward and toward the foot to remove the fragment.
   6. The surgery concludes when we have direct visualization of the root release.

b) Central, posterolateral hernias with cranial migration:

The choice of drill is an important step in performing the procedure:

- Cutting drill (3.5 mm).
- Diamond drill (3.5 mm).
- Conical drill without protection (7 × 3 mm).
- Conical drill with protection (5 × 3.5 mm). Begin with the conical drill (SGT) without protection and perform final touches with the cutting drill. For effective and safe drilling, use the lateral part of the drill and avoid high-speed lateral-to-medial movements to prevent injury to structures in the lateral recess.
- The facets extend approximately 1 cm from their junction with the pedicle to their tip, so three holes with a 3.5-mm drill are sufficient to cover the entire facet (▶ Fig. 7.1a).
- *Marking the drilling:* Make three holes—one at the base of the facet, another in the middle third, and one adjacent to the tip of the facet (▶ Fig. 7.1b).
- In cases of pediculectomy, 1.5 mm drill diameters below the junction of the pedicle with the facet.
- With a joystick, hand-foot-hand-head, connect the three points and enter the lateral facet. Initially, you will observe the trabecular structure of the facet, and after a few millimeters, the inner cortex of the SAP will be visible (▶ Fig. 7.1c).
- Use a 3.5-mm cutting or diamond drill to drill the inner cortex of the SAP. According to navigation principles, work with the endoscope rotated 90 degrees to either side to see where the drill is drilling and perform

Table 7.2 Composition of movements to grab the herniated disk

Location	Clamp forceps positioning	Triangulation	Joystick
Central	Medial	Endoscope	Down-hand
Posterolateral	Medial	Endoscope	Upper hand
Foraminal	Lateral/cranial	Endoscope	Medial
Extraforaminal	Lateral/cranial	Endoscope	Medial
Cranial migration	Cranial	Clamp forceps	Hand–foot
Caudal migration	Caudal	Clamp forceps	Head–hand

from: Kim et al,Video Atlas of Endoscopic Spine Surgery and Procedures (9781684207053)
© 2026. Thieme. All rights reserved.

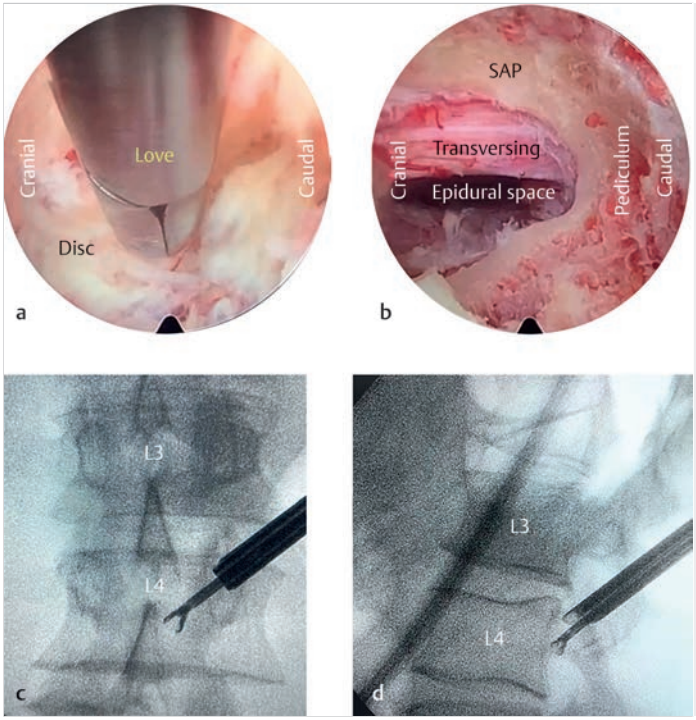

Fig. 7.1 Images of endoscopic spinal surgery, including anatomical views and surgical instruments. **(a)** Burr defines the size of the facet—each burr is 3.5 mm. **(b)** The three drill holes mark the boundaries of the facet. **(c)** The three drilling points are connected until the trabecular bone and the inner cortex of the facet are exposed. **(d)** The Kerrison punch is used to remove the inner cortex of the facet.

joystick movements with a combination of down-hand and hand–foot/head movements.

- Use a Kerrison punch to resect the remaining inner cortex of the SAP, yellow ligament of the lateral recess, and adjacent to the tip of the SAP (▶ Fig. 7.1c).
- Identify the traversing root.
- Leave the yellow ligament open only at the end, as its resection may lead to possible bleeding from the Batson venous plexus.
- In summary:
  - Limits of drilling.
  - Connecting the three holes.
  - Drill the internal cortex of the SAP.
  - Resection of the ligament of the recess and the tip of the SAP.
  - First, identify the disk fragment; dissect it using bipolar, hooks, and Love forceps; and remove the fragment. Position the hand medially and cranially, triangulating with the forceps, and perform joystick movements down-hand and toward the foot to remove the fragment. The surgery concludes when we have a direct visualization of the root release (▶ Fig. 7.2).

c) Central, posterolateral hernias with caudal migration: pediculectomy

1. *Drilling for pediculectomy:* If pediculectomy is necessary, extend it to the upper one-third of the pedicle, identifying the pedicle cortex due to its axis.
   a) Mark the three points for foraminoplasty and add a fourth hole below the angle between the facet and the pedicle. Pay attention to being in a plane parallel and close to the posterior line of the vertebral body.
   b) Combine the holes and visualize the trabecular bone of the facet and pedicle.
   c) Resect the internal cortex and the yellow ligament of the facet.
   d) Resect the internal and external cortices of the pedicle.
   e) Identify the disk fragment; dissect it using bipolar, hooks, and Love forceps; and remove the fragment (▶ Fig. 7.3a–c).
   f) Position the hand medially and caudally, triangulating with the forceps, and perform joystick movements down-hand and toward the head to remove the fragment.
   g) The surgery concludes when we have direct visualization of the root release (▶ Fig. 7.3b).

from: Kim et al,Video Atlas of Endoscopic Spine Surgery and Procedures (9781684207053)
© 2026. Thieme. All rights reserved.

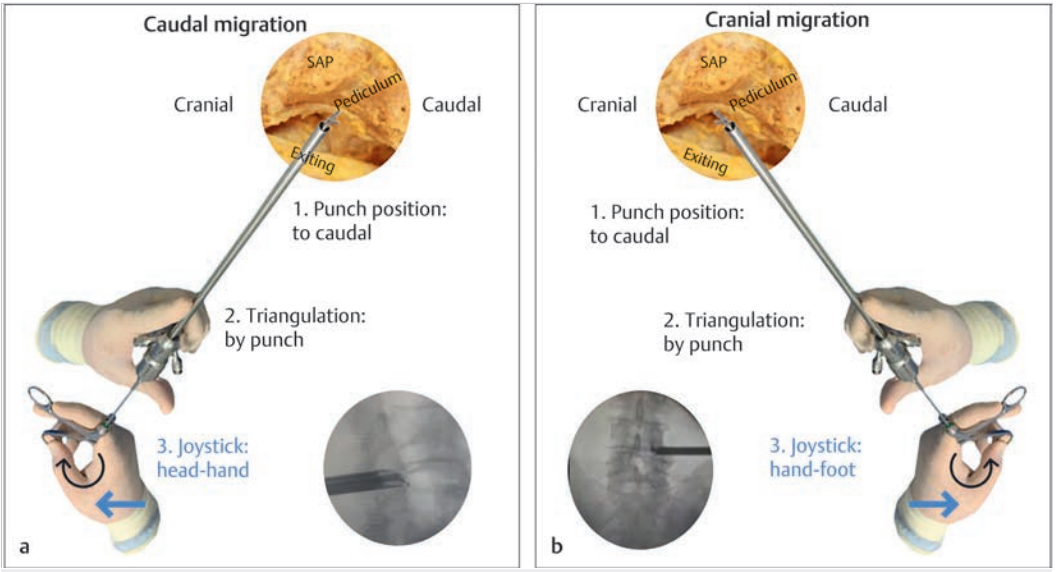

Fig. 7.2 Illustration demonstrating the hand position during high migrated disk herniation. **(a)** Caudal migration: 1. Punch positioned caudally; 2. Triangulation using the punch; 3. Joystick hand placement on the head. **(b)** Cranial migration: 1. Punch positioned caudally; 2. Triangulation using the punch; 3. Joystick hand placement on the foot. SAP, superior articular process.

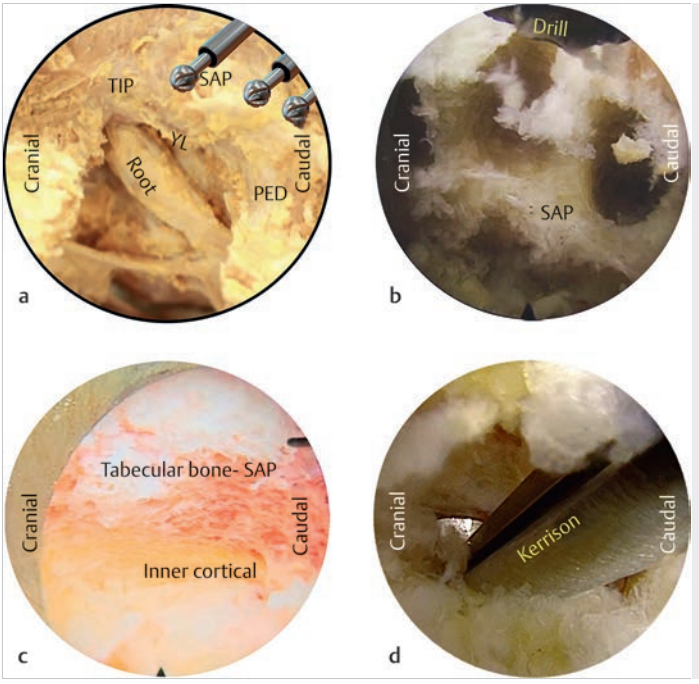

Fig. 7.3 Intraoperative and X-ray images of the Love forceps removing disk herniation. **(a)** Diskectomy. **(b)** Final view: pediculectomy. **(c)** Anteroposterior view X-ray of the Love forceps removing the intervertebral disk. **(d)** Lateral view X-ray of the Love forceps removing the intervertebral disk. SAP, superior articular process.

from: Kim et al,Video Atlas of Endoscopic Spine Surgery and Procedures (9781684207053)
© 2026. Thieme. All rights reserved.

Final Maneuvers

1. Perform nucleoplasty aiming to reduce recurrence.
2. Perform annuloplasty and invert the edges of the fibrous ring.
3. Perform washout, keep irrigation running, and connect aspirators to the outflow for 1 minute.
4. Close irrigation and dry the foraminal cavity.
5. Infiltrate Decadron; 1 ampoule.
6. Closure with Nylon or Monocryl 3–0.
7. Dressing.

7.14 Possible Complications

The transforaminal approach and manipulation of the dorsal root ganglion predispose to an unpleasant complication called dysesthesia. Other not uncommon complications include postoperative hematomas, insufficient resection, recurrence, and, in some cases, transient neurological deficit.[14,15]

References

[1] Lee S, Kim SK, Lee SH, et al. Percutaneous endoscopic lumbar discectomy for migrated disc herniation: classification of disc migration and surgical approaches. Eur Spine J. 2007; 16(3):431–437

[2] Tumialán LM, Madhavan K, Godzik J, Wang MY. The history of and controversy over Kambin's triangle: a historical analysis of the lumbar transforaminal corridor for endoscopic and surgical approaches [published correction appears in World Neurosurg. 2021 Apr;148:272. doi: 10.1016/j.wneu.2020.12.115]. World Neurosurg. 2019; 123:402–408

[3] Muthu S, Ramakrishnan E, Chellamuthu G. Is endoscopic discectomy the next gold standard in the management of lumbar disc disease? Systematic review and superiority analysis. Global Spine J. 2021; 11(7):1104–1120

[4] Hofstetter CP, Ahn Y, Choi G, et al. AOSpine Consensus Paper on Nomenclature for Working-Channel Endoscopic Spinal Procedures [published correction appears in Global Spine J. 2021 Jun;11(5):819. doi: 10.1177/2192568221995767]. Global Spine J. 2020; 10(2) Suppl:111S–121S

[5] Gore S, Yeung A. The "inside out" transforaminal technique to treat lumbar spinal pain in an awake and aware patient under local anesthesia: results and a review of the literature. Int J Spine Surg. 2014; 8:28

[6] Lewandrowski KU, Dowling Á, Calderaro AL, et al. Dysesthesia due to irritation of the dorsal root ganglion following lumbar transforaminal endoscopy: analysis of frequency and contributing factors. Clin Neurol Neurosurg. 2020; 197:106073

[7] Lübbers T, Abuamona R, Elsharkawy AE. Percutaneous endoscopic treatment of foraminal and extraforaminal disc herniation at the L5-S1 level. Acta Neurochir (Wien). 2012; 154(10):1789–1795

[8] Fiorenza V, Ascanio F. Percutaneous endoscopic transforaminal outside-in outside technique for foraminal and extraforaminal lumbar disc herniations-operative technique. World Neurosurg. 2019; 130:244–253

[9] Choi KC, Lee JH, Kim JS, et al. Unsuccessful percutaneous endoscopic lumbar discectomy: a single-center experience of 10,228 cases. Neurosurgery. 2015; 76(4):372–380, discussion 380–381, quiz 381

[10] Ahn Y, Kim JE, Yoo BR, Jeong YM. A new grading system for migrated lumbar disc herniation on sagittal magnetic resonance imaging: an agreement study. J Clin Med. 2022; 11(7):22

[11] Pertile ME, de Assunção Bicca Y, Maccari PM, et al. Advancing education in endoscopic spinal navigation: novel methods and technical note. Cureus. 2023; 15(4):e37017

[12] Mysliwiec LW, Cholewicki J, Winkelpleck MD, Eis GP. MSU classification for herniated lumbar discs on MRI: toward developing objective criteria for surgical selection. Eur Spine J. 2010; 19(7):1087–1093

[13] Letchuman V, Agarwal N, Mummaneni VP, et al. Awake spinal surgery: simplifying the learning curve with a patient selection algorithm. Neurosurg Focus. 2021; 51(6):E2

[14] Ju CI, Lee SM. Complications and management of endoscopic spinal surgery. Neurospine. 2023; 20(1):56–77

[15] Kwon WK, Hur JW. Overview and prevention of complications during fully endoscopic lumbar spine surgery. Journal of Minimally Invasive Spine Surgery and Technique. 2023; 8(2):136–144

from: Kim et al,Video Atlas of Endoscopic Spine Surgery and Procedures (9781684207053)
© 2026. Thieme. All rights reserved.

8 Full-Endoscopic Lumbar Transforaminal Diskectomy with Foraminoplasty at L5–S1 for Huge Disk Herniations

Cristian Correa-Valencia, Diego Contreras Salazar, Matías Nahuelpan, and Jin-Sung Kim

8.1 Disease Profile

Huge disk herniation (HDH), also referred to as a massive disk herniation, is often a concern for clinicians because it has the potential to generate catastrophic consequences, such as cauda equina syndrome.[1] According to a consensus, HDH is defined as a condition when the herniated disk material occupies ≥ 50% of the anteroposterior (AP) diameter of the spinal canal, as observed on magnetic resonance (MR).[2,3]

Transforaminal endoscopic lumbar diskectomy (TELD) is an alternative to the full-endoscopic interlaminar approach in cases of recurrent disk herniations.[4]

In this chapter, we provide a step-by-step guide for performing this procedure.

8.2 Synonyms

Full-endoscopic posterolateral approach, monoportal endoscopic posterolateral approach, trans-SAP foraminoplasty

8.3 Keywords

Massive disk herniations, endoscopic, foraminoplasty, diskectomy, transforaminal

8.4 Definition

Full-endoscopic transforaminal diskectomy with foraminoplasty is a minimally invasive surgical procedure used as an alternative to treat herniated disks located in the spinal space as posterolateral disk herniations.

8.5 Classification of the Technique Compared to Other Procedures

- Open diskectomy is a procedure that has progressively evolved towards less and less invasive techniques.[5]
- Since the 1990s, microdiskectomy has been established as the gold standard, after becoming popular in 1978 in the United States.[5] However, other less invasive techniques have positioned themselves as an option to be the new gold standard in the coming decades.[6] Among these alternatives are endoscopic surgery, which can be performed via transforaminal, extraforaminal, or interlaminar routes, according to the AO Spine terminology classification.[7]
- Full-endoscopic surgery has been shown to reduce complications such as infection, bleeding, durotomy, and days of hospitalization, even in lumbar stenosis surgery performed under the microscope.[8]

8.6 Indications

Alternative to full-endoscopic interlaminar diskectomy at L5–S1 in cases of the following:

- Low iliac crest.
- Large foramen.
- Recurrent disk herniations.

8.7 Contraindications

- Associated segmental instability.
- Narrow foramen.
- High iliac crest.
- High disk migration.
- Severe deformities.

8.8 Education and Special Risks

Up to 30% cases of dysesthesia have been reported to be due to irritation of the dorsal root ganglion (DRG).[9]

8.9 Preparatory Diagnostics

- An extensive magnetic resonance imaging (MRI) evaluation should be performed, and an AP and lateral spine X-ray should be requested to evaluate the height of the iliac crests.
- In patients with previous surgery, a computed tomography (CT) scan can contribute to planning for the presence of associated calcifications.

from: Kim et al,Video Atlas of Endoscopic Spine Surgery and Procedures (9781684207053)
© 2026. Thieme. All rights reserved.

- In the MRI, the position of the L5 root ganglion should be specified as much as possible, as well as its percentage of occupation within the foramen, given its variability, particularly in L5–S1.[10]

8.10 Anesthesia

- General or local anesthesia can be utilized. Despite the potential benefit of awake patient feedback, evidence has shown no increased incidence of DRG irritation with general anesthesia based on protocols that do not use muscle relaxation during surgery, allowing motor monitoring by the surgical assistant.[11]
- Recent evidence shows that local anesthesia is less expensive. In contrast, general anesthesia shows better global analgesia in leg and back pain up to 2 weeks postoperatively, although long-term results are similar.[11]
- Other protocols with epidural analgesia for frail patients have been tried, also showing better analgesia control with the epidural scheme.[12]

8.11 Personnel, Material, and Adjustment Technology

Equipment: Like any uniportal endoscopic diskectomy procedure, the essential equipment includes the following:

- A working channel spinal endoscope. The diameter of the working channel varies depending on the manufacturer. A minimum of 3.7 mm is recommended to shorten the operative time.
- *Endoscopic dissectors:* Straight and angulated dissectors are necessary to perform a gentle and safe dissection of the exiting nerve root and ganglion.
- *Endoscopic flexible coagulators:* Both bipolar and radiofrequency coagulation can be used.
- Endoscopic forceps, scissors, and punches.

Given the usual nature of an undersized foramen at L5–S1, you should be prepared to work in the bony component of the superior articular process (SAP). We recommend the use of motors with high-speed burrs to control the resection under direct vision to decrease the risk of DRG irritation in a foramen where the position of the DRG of the L5 root is very variable.[10]

Therefore, it is essential to have a complete set of bone-removing instruments available, even for these extraforaminal approaches.

8.12 Implementation

8.12.1 Preoperative Planning

- *Clinical evaluation:* As a routine, gently verify the clinical correlation between symptomatology and MRI findings.
- *MR:* Verify the position of the hernia and the absence of high-grade migration. Verify the percentage of occupation of the DRG of L5 within the foramen, as well as the precise position of this ganglion.
- *AP and lateral radiography:* Look for iliac crest height. The high iliac crest is defined as the outline of the iliac crest above the mid-L5 pedicle in lateral radiography.[13]
- *CT scan:* Since a calcified hernia is a possibility in cases of previous surgery, it is advisable to obtain this study prior to surgery.

8.12.2 Skin Marking

- In the OR, the C-arm is positioned under an AP projection with an inclination that provides a clear view of the two endplates of the pathological disk space (▶ Fig. 8.1a).
- Two perpendicular lines are then drawn on the patient's skin: one marking the disk level and the other the midline. The distance from the midline is marked along the disk level line; in general, for posterolateral disk herniations, this distance ranges from 8 to 9 to 12 cm, paying attention to avoid going through the abdomen according to the previous analysis of MR.
- Position the arch in lateral projection and verify that the chosen distance from the midline does not exceed the line joining the spinous processes (▶ Fig. 8.1b).[14]

8.12.3 Access

- Reposition the C-arm in AP projection. Only advance the needle in AP projection without exceeding the medial line that joins the medial border of the pedicles.[14] Once this area is reached, place the C-arm in a lateral position, verifying that it is located in the inferior area of the foramen,[14] ideally as close as possible to the superior border of the S1 pedicle.

from: Kim et al,Video Atlas of Endoscopic Spine Surgery and Procedures (9781684207053)
© 2026. Thieme. All rights reserved.