Achondroplasia

***FGFR3* gain-of-function mutation, 20% autosomal dominant and 80% sporadic**

Diagnosed by genetic testing, antepartum ultrasound, and familial history

Anatomical features include short pedicles, narrow interpedicular distances, square ilia, narrow sacrosciatic notches, basilar invagination, and spinal stenosis

ETIOLOGY

- Achondroplasia is caused by a gain-of-function mutation in the *FGFR3* gene, which encodes a key regulator of bone growth. This mutation disrupts the proliferation and differentiation of chondrocytes, leading to defects primarily in cartilaginous bone development. As a result, virtually all clinical manifestations of the condition stem from abnormalities in cartilage
- Achondroplasia can be diagnosed prenatally with genetic testing in cases showing ultrasound findings suggestive of the condition and family history, as per the International Achondroplasia Consensus Statement Group. Most cases are diagnosed in infancy. Over 80% of cases are due to sporadic mutations, and advanced paternal age is a known risk factor

FEATURES

- Short stature with rhizomelic disproportion, macrocephaly, thoracolumbar kyphosis, and lumbar hyperlordosis. Skeletal abnormalities include short limbs, short pedicles, narrow interpedicular distances, square ilia, and narrow sacrosciatic notches, along with basilar invagination and spinal stenosis. Hydrocephalus affects 15–50% of individuals

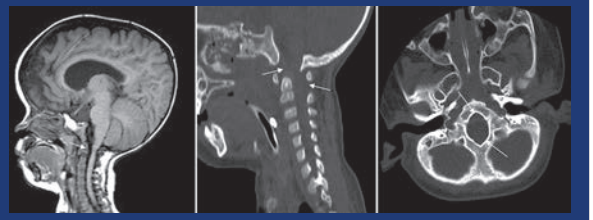

An 8-year-old boy with achondroplasia displaying basilar invagination and cervical spinal stenosis

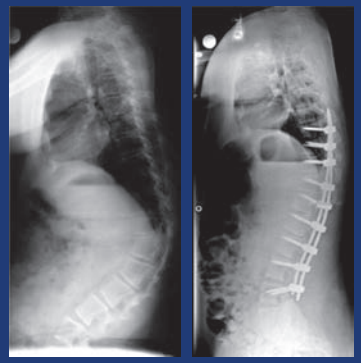

Radiographs of a 17-year-old boy with achondroplasia before and after T8–L4 decompression and fusion indicated for neurogenic claudication

TREATMENT

- Multidisciplinary and lifelong supportive care
- Foramen magnum decompression for cervicomedullary compression in patients with symptomatic myelopathy or syringomyelia, CSF diversion for symptomatic hydrocephalus, and decompression for spinal deformity and stenosis

Further Readings

1. King JA, Vachhrajani S, Drake JM, Rutka JT. Neurosurgical implications of achondroplasia. J Neurosurg Pediatr 2009;4(4):297–306
2. Pauli RM. Achondroplasia: a comprehensive clinical review. Orphanet J Rare Dis 2019 ;14(1):1
3. Greenberg MS. Greenberg's Handbook of Neurosurgery, 10th ed. Thieme Medical Publishing Group; 2023

Nitin Agarwal
David T. Fernandes Cabral
Samuel Adida

Thieme

from: Agarwal et al, Neurosurgery Infographics (9781684207671)
© 2026. Thieme. All rights reserved.

Acromegaly

Diagnosis is confirmed by measuring elevated IGF-1 and failure to suppress GH after an oral glucose tolerance test

Pharmacologic treatment includes somatostatin analogs, GH receptor antagonists, and dopamine agonists

Neurosurgical intervention consists of gross total surgical resection, and radiotherapy or radiosurgery as adjuvant treatment or as indicated for recurrent disease

PRESENTATION

- Acromegaly is most commonly caused by WHO Grade 1 pituitary somatotroph adenomas. These tumors are classified as microadenomas (<10 mm) or macroadenomas (>10 mm) and are responsible for excessive production of GH
- In adults, excess GH leads to abnormal growth, particularly in the hands, feet, and facial features, while in children, it results in gigantism before the closure of the epiphyseal plates. Genetic factors, such as mutations in MEN1, can increase the likelihood of developing acromegaly
- MRI typically shows well-encapsulated contrast-enhancing masses. Dynamic contrast-enhanced MRI improves the sensitivity for detecting microadenomas

RADIOGRAPHIC FEATURES

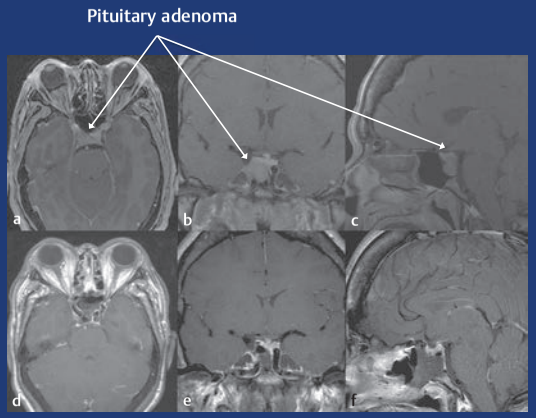

MRI of a 57-year-old patient with acromegaly. Preoperative sequences demonstrate a sellar tumor with extension along the right retrosellar area. Postoperative sequences show resection with use of an endoscopic endonasal approach

TREATMENT

- Pharmacological treatments include somatostatin receptor ligands like octreotide and lanreotide, as well as the GH receptor antagonist pegvisomant. Cabergoline, a dopamine agonist, can be considered in patients with mild acromegaly or those who are resistant to somatostatin analogs
- Transsphenoidal resection is the first-line intervention, offering immediate GH reduction and diagnostic tissue. While surgery often leads to remission, treatment is frequently multimodal. Remission is more likely with lower preoperative GH levels, smaller tumor size, and extra pseudocapsular resection, but macroadenomas and cavernous sinus invasion are linked to lower remission rates
- Radiotherapy is considered for residual or enlarging tumors when surgery and medical treatments fail. Radiosurgery offers similar efficacy to conventional radiotherapy with fewer side effects but has a higher risk of stroke

Further Readings

1. Marquez Y et al. Surgery and radiosurgery for acromegaly: a review of indications, operative techniques, outcomes, and complications. Int J Endocrinol 2012;2012:386–401
2. Zahr R, Fleseriu M. Updates in diagnosis and treatment of acromegaly. Eur Endocrinol 2018;14(2):57–61
3. Greenberg MS. Greenberg's handbook of neurosurgery, 10th ed. Thieme Medical Publishing Group; 2023

Nitin Agarwal
David T. Fernandes Cabral
Samuel Adida

Thieme

from: Agarwal et al, Neurosurgery Infographics (9781684207671)
© 2026. Thieme. All rights reserved.

Arachnoid Cysts

- **Most common intracranial locations are the middle cranial fossa, posterior cranial fossa, and suprasellar region**
- **The thoracic spine is the most common region for spinal arachnoid cysts**

Galassi's classification of arachnoid cysts based on CT and CT cisternography:

- **Type I: Small, spindle-shaped cyst in the anterior temporal fossa; no mass effect or midline displacement; communicates with the subarachnoid space**
- **Type II: Medium-sized, quadrangular cyst extending along the Sylvian fissure; partially communicates with the subarachnoid space**
- **Type III: Large cyst involving the entire Sylvian fissure, displacing midline structures and compressing frontal and parietal lobes; minimal communication with the subarachnoid space.**

PRESENTATION

- Arachnoid cysts are classified as primary developmental cysts or secondary cysts. Primary cysts result from in utero splitting of the arachnoid membranes, leading to CSF accumulation. Secondary cysts develop following trauma, surgery, or infection
- Approximately 95% of patients with arachnoid cysts are asymptomatic, with an average pediatric diagnosis age of 6 years
- The presentation of arachnoid cysts depends on their size and location. Small cysts are typically asymptomatic, while large cysts may cause focal deficits. Arachnoid cysts tend to stop expanding after the age of 4 years
- Symptoms include headache, dizziness, nausea, vomiting, altered mental status, ataxia, seizures, and tinnitus. Rare but notable presentations include intracranial hypertension, visual deterioration, endocrinopathy, and "bobble-head doll syndrome"

RADIOGRAPHIC FEATURES

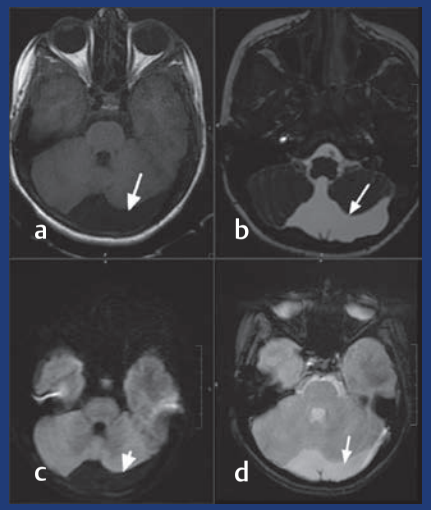

Axial images of the posterior fossa reveal a cerebellar arachnoid cyst exhibiting mass effect. It is hypointense on (a) T1 MRI, hyperintense on (b,d) T2 MRI, and does not exhibit (c) DWI restriction

TREATMENT

- Arachnoid cysts are most commonly located intracranially, with the middle cranial fossa being the predominant site. Other frequent locations include the cerebellopontine angle, suprasellar and quadrigeminal cisterns, cerebral convexities, and cisterna magna. Arachnoid cysts may also occur along the spinal cord
- Arachnoid cysts should be differentiated from epidermoid cysts, which are usually more lobulated and demonstrate diffusion restriction on imaging. In the retrocerebellar space, arachnoid cysts should be differentiated from mega cisterna magna, which does not present with mass effect or contrast enhancement
- Surgical intervention includes microsurgical fenestration via craniotomy, endoscopic fenestration, and cysto-peritoneal shunting

Further Reading

1. Mustansir F, Bashir S, Darbar A. Management of arachnoid cysts: a comprehensive review. Cureus 2018;10(4):e2458
2. Greenberg MS. Greenberg's Handbook of Neurosurgery. 10th ed. Stuttgart, Germany: Thieme Medical Publishing Group; 2023

Nitin Agarwal
David T. Fernandes Cabral
Samuel Adida

Thieme

from: Agarwal et al, Neurosurgery Infographics (9781684207671)
© 2026. Thieme. All rights reserved.

Arteriovenous Malformations (AVM)

Annual risk of hemorrhage is

1–3%

Genetic risks

- **Osler–Weber–Rendu syndrome**
- **Sturge Weber syndrome**
- ***KRAS* and *SMAD4/9* mutations**

Spetzler-Martin grading scale for arteriovenous malformations

Graded feature	Points
Size	
Small (<3 cm)	1
Medium (3–6 cm)	2
Large (>6 cm)	3
Eloquence of adjacent brain	
Noneloquent	0
Eloquent	1
Draining veins	
Superficial	0
Deep	1

ETIOLOGY

- AVMs are anomalous direct shunts between cerebral arteries and veins that convalesce into a vascular nidus
- Typically, a single feeding artery with a well-defined internal and external elastic lamina. Veins lack an external elastic lamina and have a thin or poorly developed internal elastic lamina

PRESENTATION

- Intracranial AVMs may be identified during the evaluation of strokes, seizures, CN palsies, focal neurological deficits, or incidentally
  - Acute hemorrhage (65%)
  - Seizures (20%)
  - Incidental finding (15%)
  - Focal neurological deficits
    - Ischemic regional "steal" phenomenon
    - Mass effect
  - Pulsatile tinnitus
  - Headache

RADIOGRAPHIC FEATURES

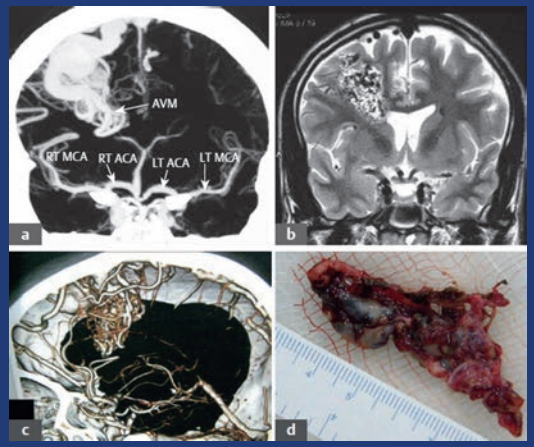

(a) CTA and (b) T2 MRI of a motor cortex AVM. (c) A 3D-reconstructed CTA can better characterize the AVM. (d) Resected specimen

TREATMENT

- The Spetzler–Martin AVM grading scale is used to determine risk of open surgical resection. Resection aims to remove the nidus *en bloc*. High success rates but involves a craniotomy, longer recovery, and higher morbidity. Best for Spetzler–Martin grades I–III, with scores ≤ 6 preferred
- Endovascular embolization controls bleeding, targets simple AVMs, and aids in surgery or SRS. Multi-stage techniques use agents such as onyx and PVA but carry a ~7% risk of complications including hemorrhage and stroke
- SRS is effective for small and medium AVMs in the deep brain structures. Achieves 60–80% obliteration in 3–5 years but risks radiation changes (~36%, symptomatic in ~10%). AVM embolization may negatively affect likelihood of obliteration after SRS
- Ruptured AVMs often require surgery due to high rebleeding risk. The ARUBA and SAIVM trials have investigated outcomes for unruptured AVMs

Further Reading

1. Zyck S, Davidson CL, Sampath R et al. Arteriovenous malformations of the central nervous system. In: StatPearls [Internet]. Treasure Island, FL: StatPearls Publishing; 2024
2. Chen CJ, Ding D, Derdeyn CP et al. Brain arteriovenous malformations: a review of natural history, pathobiology, and interventions. Neurology 2020;95(20):917–927
3. Greenberg MS. Greenberg's Handbook of Neurosurgery. 10th ed. Stuttgart, Germany: Thieme Medical Publishing Group; 2023

Nitin Agarwal
David T. Fernandes Cabral
Samuel Adida

Thieme

from: Agarwal et al, Neurosurgery Infographics (9781684207671)
© 2026. Thieme. All rights reserved.

Brain Abscesses

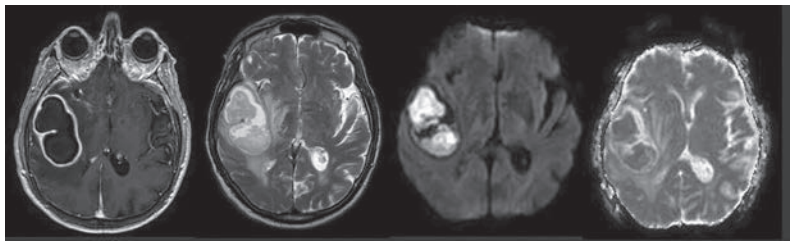

T1 enhanced T2 DWI ADC map

- **Staphylococci spp. and Streptococcus spp. are common in patients with a history of neurosurgery**
- **Staphylococcus spp., Streptococcus spp., Clostridium spp., and Enterobacteriaceae spp. are found in patients with open head trauma**
- **Fungal infections, Toxoplasma gondii, Staphylococcus spp., Streptococcus spp., and Pseudomonas are seen in immunocompromised patients**

PRESENTATION

- Cerebral abscesses are rare, with an estimated 1,500–2,500 cases annually in the United States. Symptoms arise primarily due to increased ICP, including headache, nausea, vomiting, and lethargy. Notably, hemiparesis and seizures occur in 30–50% of cases, with symptom progression typically more rapid than that seen in neoplasms
- Cerebral abscesses commonly result from hematogenous spread of infection, post-surgical complications, or penetrating injuries. They may also occur via contiguous spread (e.g., from frontal sinus or mastoid infections) or, less commonly, through transcoelomic routes (e.g., direct extension through body cavities)
- Seizures and hemiparesis are the most common presenting features. While the classic triad of headache, focal neurological deficit, and fever is often cited, it is observed in only ~20% of patients

RADIOGRAPHIC FEATURES

- On CT with contrast, cerebral abscesses often exhibit a double rim sign, with an outer hypodense and inner hyperdense rim. A uniform, iso-, or hyperdense ring surrounds a hypodense core, with adjacent low-density vasogenic edema
- On MRI, T1 shows a hypointense core with peripheral ring enhancement and surrounding vasogenic edema. On T2/FLAIR, the core appears hyperintense with surrounding edema; the capsule may appear as a thin rim of low signal
- DWI/ADC is key for diagnosis, revealing central diffusion restriction. In immunocompromised patients, this may be absent. SWI highlights the capsule as a smooth low-intensity rim, with the dual rim sign further aiding in diagnosis

TREATMENT

- Blood cultures, WBC count, and β-d-glucan suggest invasive fungal disease. In immunocompromised patients, lab findings alone may support a presumptive diagnosis of *Toxoplasma gondii*. The role of lumbar puncture and CSF analysis may be explored based on the clinical context
- Conservative medical management may suffice for small abscesses without significant mass effect or symptoms
- Management includes biopsy if indicated, and surgical excision or needle aspiration for abscesses near the ventricles. Antimicrobial therapy is essential and may be tailored to the underlying pathogen. Dexamethasone is used to reduce vasogenic edema

Further Reading

1. Bokhari MR, Mesfin FB. Brain abscess. In: StatPearls [Internet]. Treasure Island, FL: StatPearls Publishing; 2024
2. Greenberg MS. Greenberg's Handbook of Neurosurgery. 10th ed. Stuttgart, Germany: Thieme Medical Publishing Group; 2023

Nitin Agarwal
David T. Fernandes Cabral
Samuel Adida

Thieme

from: Agarwal et al, Neurosurgery Infographics (9781684207671)
© 2026. Thieme. All rights reserved.

Brainstem Cavernoma-Part I

The familial form of CM comprises approximately 6–50% of all cases and are derived from mutations in the CCM1-3 genes

CLINICAL OVERVIEW

Introduction
- Brainstem cavernous malformations (CMs) are low-flow vascular malformations composed of dysplastic capillaries with no normal intervening brain parenchyma. Their deep, eloquent location poses high risk of hemorrhage, leading to significant morbidity even with small-volume bleeds. Surgical intervention is challenging due to their proximity to critical neurovascular structures, necessitating a careful risk–benefit assessment
- The average age of adult presentation is in the fourth or fifth decade of life. Children present in a bimodal pattern with peaks at 0–2 and 13–16 years of age

Pathophysiology
- Thin-walled, leaky vascular channels with hemosiderin deposition, prone to microbleeding and overt hemorrhage
- Most commonly found in the pons (~60%), followed by the midbrain (~20%) and medulla (~15%)
- May be sporadic (single lesion) or familial (multiple lesions), the latter associated with CCM1-3 gene mutations (autosomal dominant inheritance)
- Adjacent developmental venous anomalies (DVAs): Frequently coexist with cavernomas and should be preserved during surgery to avoid venous infarction

Clinical Presentation
- Stepwise neurological decline due to recurrent microhemorrhages
- Focal neurological deficits:
    - Pontine lesions: Hemiparesis, facial weakness, dysarthria, diplopia (CN VI)
    - Midbrain lesions: Oculomotor palsy (CN III), contralateral hemiparesis (Weber's syndrome)
    - Medullary lesions: Dysphagia, vertigo, respiratory dysfunction (lower CN involvement)
- Acute hemorrhage → sudden worsening of symptoms, often requiring urgent intervention
- Seizures are rare, as the brainstem is not epileptogenic

Further Reading
1. Teo C, Sughrue M, eds. Principles and Practice of Keyhole Brain Surgery. 1st ed. Stuttgart: Thieme; 2015

Nitin Agarwal
David T. Fernandes Cabral
Samuel Adida

Thieme

from: Agarwal et al, Neurosurgery Infographics (9781684207671)
© 2026. Thieme. All rights reserved.

Brainstem Cavernoma-Part II

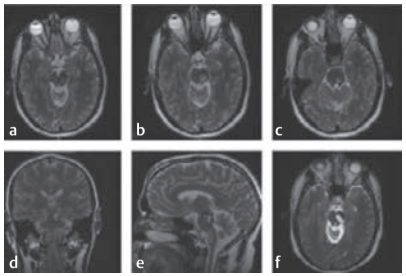

Brainstem cavernomas (BCs) account for 18–35% of CNS cavernomas and can present with hemorrhage or progressive neurological deficit. Approximately 57% of the cavernomas occur in pons followed by midbrain (14%), pontomedullary junction (12%), and medulla (5%).

IMAGING

- MRI is the gold standard: T2weighted imaging:
  - Type I CM contain subacute hemorrhage characterized by a hemosiderin core, which is hyperintense on T1 and T2 sequences
  - Type II CM with loculated areas of hemorrhage are surrounded by gliotic tissue displaying a reticulated mixed signal on appearance
  - Type III lesions, typically seen in familial CM, contain chronic resolved hemorrhage, with T1, T2, and gradient echo sequences displaying an isointense lesion. Familial lesions are also thought to more frequently lack a developmental venous anomaly, which becomes apparent on contrast-enhanced MRI
  - Type IV lesions appear similar to telangiectasias and are only seen on gradient echo MRI as small punctate hypointense signals
- Gradient echo (T2) and SWI (susceptibilityweighted imaging): Most sensitive for detecting hemosiderin deposition from prior hemorrhages
- T1-weighted imaging: Acute hemorrhage may appear hyperintense, while chronic lesions show mixed signal intensities
- FLAIR: May show perilesional edema in active hemorrhage
- CT is typically normal unless a recent hemorrhage is present but lacks specificity
- Catheter angiography is NOT indicated, as cavernomas are angiographically occult

MANAGEMENT

Observation and Serial Imaging
- Indicated for asymptomatic or mildly symptomatic lesions, particularly deep-seated ones
- Follow-up with MRI to assess interval hemorrhage risk

Surgical Resection
- Reserved for symptomatic, recurrent hemorrhages or progressive neurological deterioration
- Operative approach dictated by safest pial or ependymal entry zone to minimize brainstem disruption:
  - Midbrain: Interhemispheric transtentorial or subtemporal approach
  - Pons: Extended retrosigmoid, suboccipital, or lateral supracerebellar-infratentorial approach
  - Medulla: Far-lateral approach
- Intraoperative neuromonitoring is critical due to the high risk of permanent deficit

Stereotactic Radiosurgery (SRS)
- Controversial, generally reserved for deep, inoperable lesions
- Long-term efficacy in hemorrhage reduction remains uncertain

Nitin Agarwal
David T. Fernandes Cabral
Samuel Adida

Thieme

from: Agarwal et al, Neurosurgery Infographics (9781684207671)
© 2026. Thieme. All rights reserved.

Carotid-Cavernous Fistula-Part I

Direct CCFs are high flow, traumatic, and symptomatic, requiring urgent endovascular treatment, whereas indirect CCFs are low flow and often self-limiting

CLINICAL OVERVIEW

Introduction
- A carotid-cavernous fistula (CCF) is an abnormal connection between the carotid arterial system and the cavernous sinus. This arteriovenous shunting leads to venous congestion, ocular dysfunction, and potential neurological deficits. Early recognition and management are critical to prevent vision loss and intracranial complications

Clinical Presentation
- Classic clinical triad:
    - Pulsatile exophthalmos
    - Conjunctival injection and chemosis ("arterialized" eye)
    - Bruit over the orbit
- Other symptoms:
- Ophthalmoplegia: Cranial nerves III, IV, and VI compression from venous congestion
- Increased intraocular pressure (IOP) → Risk of glaucoma and vision loss
- Cortical venous reflux → Risk of hemorrhage or ischemic stroke (in high-risk fistulas)

Classification
- Type A (direct CCF): High-flow fistula due to direct rupture of the internal carotid artery (ICA) into the cavernous sinus, typically from trauma or aneurysm rupture, requiring urgent intervention
- Type B (indirect CCF): Low-flow fistula arising from meningeal branches of the ICA, often spontaneous or associated with hypertension, with potential for spontaneous resolution or endovascular treatment if symptomatic
- Type C (indirect CCF): Low-flow fistula supplied by meningeal branches of the external carotid artery (ECA), similar to type B in presentation and treatment considerations
- Type D (indirect CCF): Low-flow fistula with dual supply from both ICA and ECA meningeal branches, posing a slightly higher risk of persistent symptoms and requiring closer monitoring or embolization if symptomatic

Further Readings
1. Dahiya A, Dahiya S, Kumar SS, et al. Posttraumatic carotid cavernous fistula: a rare case. Indian J Neurotrauma 2021;18(02):142–145
2. Ellis JA, Goldstein H, Connolly ES Jr, Meyers PM. Carotid-cavernous fistulas. Neurosurg Focus 2012;32(5):E9

Nitin Agarwal
David T. Fernandes Cabral
Samuel Adida

Thieme

from: Agarwal et al, Neurosurgery Infographics (9781684207671)
© 2026. Thieme. All rights reserved.

Carotid-Cavernous Fistula-Part II

The classic triad—pulsatile proptosis, conjunctival injection, and orbital bruit—should prompt immediate vascular imaging, with digital subtraction angiography (DSA) as the gold standard

CLASSIFICATION

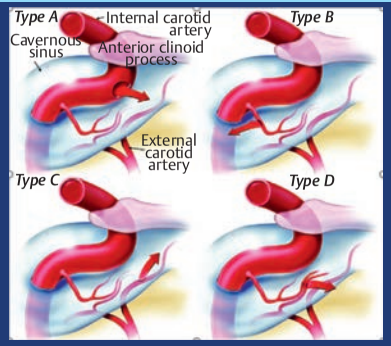

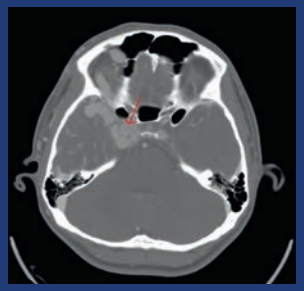

Fistulous communication between
The right intracavernous ICA

Classification of CCF
- CCFs are classified based on their vascular origin and flow dynamics:
- Direct (high-flow) CCF
- Direct communication between the ICA and cavernous sinus
- Typically traumatic or from ICA aneurysm rupture
- High-pressure shunting leads to severe orbital symptoms and cranial nerve dysfunction
- Indirect (low-flow) CCF
- Arise from dural branches of the ECA or ICA
- Often spontaneous, associated with connective tissue disorders or venous hypertension
- More insidious in onset with milder symptoms

Diagnostic Imaging
- CT/MRI with contrast: Cavernous sinus enlargement, proptosis, and enlarged ophthalmic veins
- CT/MR angiography (CTA/MRA) often misses low-flow indirect CCFs, and delayed venous-phase imaging is necessary
- CT/MRA: Noninvasive screening, identifying arterial feeders
- DSA: Gold standard for definitive diagnosis and classification, crucial for treatment planning

Nitin Agarwal
David T. Fernandes Cabral
Samuel Adida

Thieme

from: Agarwal et al, Neurosurgery Infographics (9781684207671)
© 2026. Thieme. All rights reserved.

Carotid-Cavernous Fistula-Part III

Endovascular embolization is the primary treatment modality, with transvenous access favored for indirect CCFs and transarterial techniques for direct fistulas

MANAGEMENT

Predictors of Spontaneous Resolution
- Indirect (low-flow) CCFs (types B, C, and D)
- Small fistula size
- Mild symptoms: If the patient has minimal proptosis, mild chemosis, or low-grade bruit, the fistula may resolve without intervention
- Venous drainage pattern: If the drainage is primarily anterior (ophthalmic veins) and not into the deep venous system, there is a higher chance of resolution
- Stable or improving symptoms
- No evidence of cortical venous reflux

Predictors Requiring Urgent Intervention
- Direct (high-flow) CCFs (type A): Typically due to traumatic rupture of the ICA into the cavernous sinus, typically require endovascular treatment
- Severe ophthalmologic symptoms: Progressive proptosis, severe chemosis, diplopia, or decreased visual acuity indicate worsening venous congestion
- Cortical venous reflux: Retrograde venous drainage into the cortical veins increases the risk of venous hypertension, intracranial hemorrhage, or seizures
- Intracranial hemorrhage or ischemia
- Elevated IOP leading to glaucoma: Persistent venous congestion can lead to optic neuropathy and vision loss
- Worsening neurologic deficits: If the patient develops cranial nerve palsies (especially CNs III, IV, VI) or progressive neurologic symptoms, intervention is indicated
- High-flow shunting on angiography: Large fistulas with significant arterial supply from the ICA or ECA require intervention to prevent complications

Endovascular Treatment
- Transvenous coil embolization: For indirect CCFs via the inferior petrosal sinus
- Transarterial embolization: For direct CCFs when venous access is limited
- Flow-diverting stents: Emerging therapy for certain direct fistulas
- Surgical ligation: Rarely indicated, reserved for refractory cases or inaccessible fistulas
- Escalate to surgical bypass or ICA trapping if embolization fails and the patient has persistent/worsening symptoms (vision loss, proptosis, cranial nerve deficits), cortical venous reflux with hemorrhage risk, high-flow shunting with arterial steal, recurrent fistula despite multiple embolization attempts, or ICA compromise (stenosis, dissection, pseudoaneurysm)
- *Complications*: Reperfusion hemorrhage, cranial neuropathies post-coil embolization, recurrence, and risk of ICA sacrifice

Postoperative Management

Imaging
- Early (24–48 h postprocedure): CTA or MRA to confirm fistula closure
- Routine (1–3 months posttreatment): Repeat DSA if symptoms persist or there is concern for recurrence
- Long-term (6–12 months): Imaging surveillance, especially for high-risk cases (residual shunting, bypass)

Medical Management
- IOP control: Topical and systemic agents if venous congestion persists
- Anti-inflammatory therapy: Short-term steroids for severe chemosis or orbital inflammation
- Antiplatelet/anticoagulation therapy: If stent-assisted embolization was performed

Nitin Agarwal
David T. Fernandes Cabral
Samuel Adida

Thieme

from: Agarwal et al, Neurosurgery Infographics (9781684207671)
© 2026. Thieme. All rights reserved.